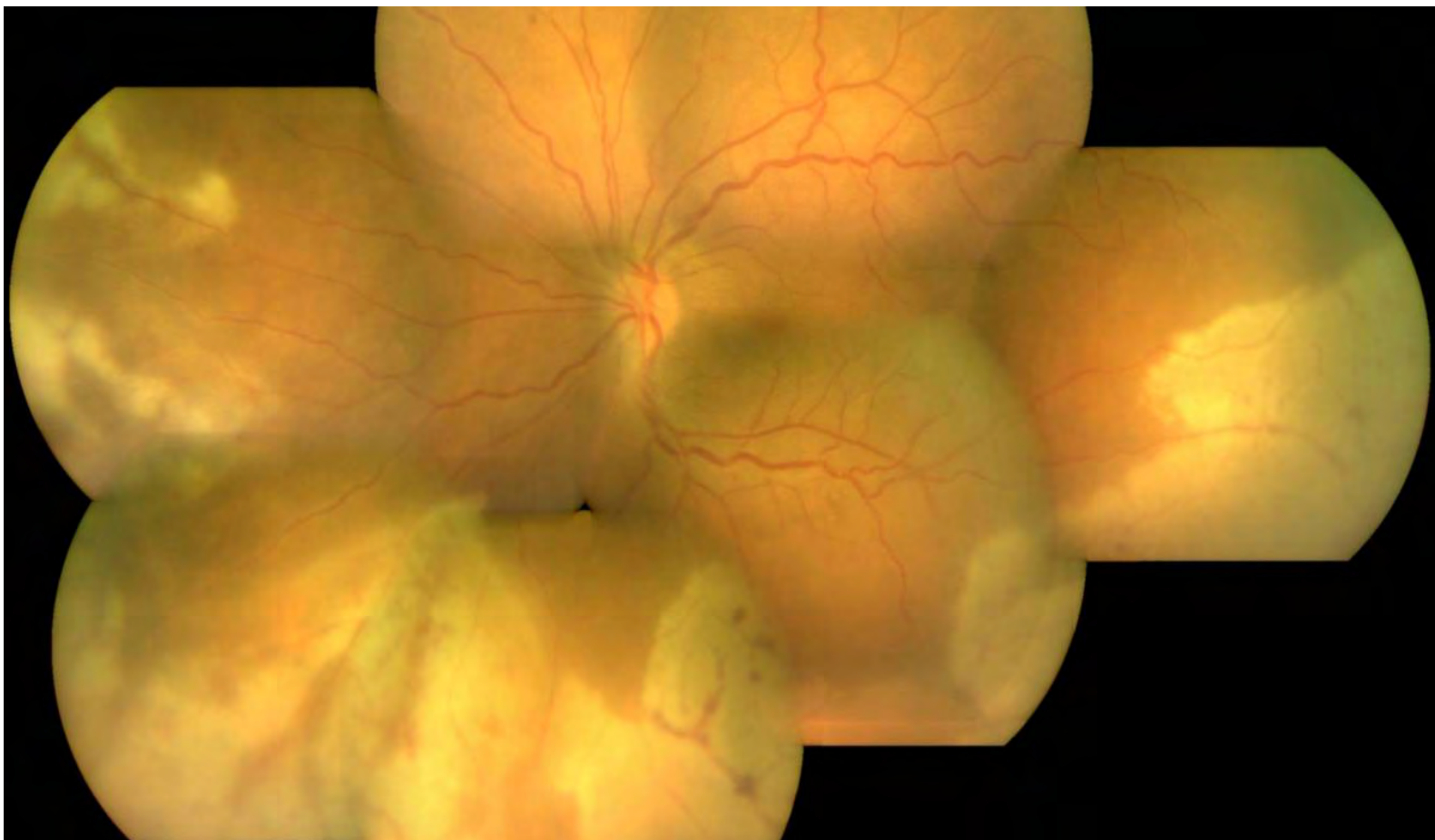


January 2019 Volume 37 No 1

# insight

Scientific Journal of  
**MEDICAL & VISION RESEARCH FOUNDATIONS**



# Editorial Team

## **Chief Editor:**

Md. Shahid Alam

## **Assistant Editors:**

Jaya Prakash V

Sharanya Sarah Abraham

Sharada R

Anuradha M

## **Section Editors:**

Shweta S Agarwal

Akila Ramkumar

Eesh Nigam

Durga Priyadarshini S

Nisar Sonam Poonam

Arshee S Ahmad

Gazal Patnaik

Prabrisha Banerjee

## **Advisory Board:**

Girish Shiva Rao

Ronnie Jacob George

Smita Vittal

Parthapratim Dutta Majumder

# Insight

Scientific Journal of Medical & Vision Research Foundations

Year: 2019

Issue: Vol. 37 | No. 1 | January 2019 | Pages 1 - 30

Typeset by: V. Deenadayalan, Sankara Nethralaya, Chennai

Printed at: Ess Zed Enterprise, 4/1 Topsia First lane Kolkata 700 039

©Medical and Vision Research Foundations



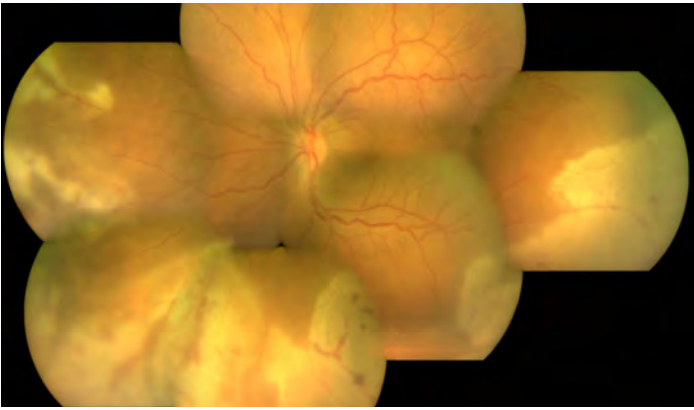
## Sankara Nethralaya – The Temple of the Eye.

It was in 1976 when addressing a group of doctors, His Holiness Sri Jayendra Saraswathi, the Sankaracharya of the Kanchi Kamakoti Peetam spoke of the need to create a hospital with a missionary spirit. His words marked the beginning of a long journey to do God's own work. On the command of His Holiness, **Dr. Sengamedu Srinivasa Badrinath**, along with a group of philanthropists founded a charitable not-for-profit eye hospital.

Sankara Nethralaya today has grown into a super specialty institution for ophthalmic care and receives patients from all over the country and abroad. It has gained international excellence and is acclaimed for its quality care and compassion. The Sankara Nethralaya family today has over 1400 individuals with one vision – to propagate the Nethralaya philosophy; the place of our work is an Alaya and Work will be our worship, which we shall do with sincerity, dedication and utmost love with a missionary spirit.

## Contents

<b>From the Editor's Desk:</b> The Grapes are no more Sour	<i>Md. Shahid Alam</i>	1
<b>Guest Editorial:</b> Characterizing the Intraocular Inflammation will Save You the Day!	<i>Prof. Amod Gupta</i>	2
<b>Original Article:</b> Intraocular Lymphomas: Challenges in Diagnosis and Management	<i>Arshee Ahmed, Sudha K Ganesh</i>	4
<b>Review Article:</b> Molecular Diagnosis of Infectious Uveitis: An Update	<i>A R Anand, Jyotirmay Biswas</i>	7
<b>Review Article:</b> Biologics: A New Paradigm in the Management of Noninfectious Uveitis	<i>Samantha Prabakaran, Ricci Allen, Amravi Shah, Jyotirmay Biswas</i>	12
<b>Case Report:</b> A Case of Sympathetic Ophthalmitis following Globe Rupture	<i>Preeti Sharma, Soumyadeep Hazra</i>	20
<b>Case Report:</b> Role of Nested Polymerase Chain Reaction and Enzyme-Linked Immunosorbent Assay of Aqueous Aspirate in a Case of Atypical Toxoplasmic Panuveitis	<i>Gazal Patnaik, Janani M.K, Jyotirmay Biswas</i>	23
<b>Nutshell:</b> Clinical and Imaging Features of Different Stages of Vogt- Koyanagi- Harada Syndrome	<i>Preeti Sharma, Soumyadeep Hazra</i>	26
<b>Photoessay:</b> Acute Retinal Necrosis	<i>Amitabh Kumar, Bhuvaneshwaran V</i>	28
<b>Photoessay:</b> Vogt Koyanagi Harada Syndrome	<i>Amitabh Kumar, Bhuvaneshwaran V</i>	29
<b>Miscellaneous:</b> Covid19: The Curse and the Cure	<i>Prabrisha Banerjee</i>	30



**Cover Page Image**

**Acute Retinal Necrosis**

**Contributed by:** Amitabh Kumar, Bhuvaneshwaran.V

## The Grapes are no more Sour

Md. Shahid Alam

Senior Consultant  
Orbit Oculoplasty  
Reconstructive and  
Aesthetic Services  
Aditya Birla Sankara  
Nethralaya  
147, Mukundapur, E M Bypass  
Kolkata 700099  
India.

mshahidalam@gmail.com

drmsa@snnmail.org



The literal meaning of Uvea is “grape”; and this one continues to remain sour for most of the practicing ophthalmologists. Uvea and the pathological processes afflicting it have always been an enigma, with diseases raising more questions than the answers we could come up with.

My very first exposure to this particular sub specialty was limited to a thin chapter of Kanski's Text Book of Ophthalmology; a somewhat wider coverage was obtained from the Uvea book of American Academy of Ophthalmology series during my post graduation days. In those heady times this was the only sub specialty where most of our knowledge was from text books with very little real-life exposure to actual signs that were described. Most of our clinical experience was limited to examining and treating patients of acute anterior uveitis. The chronic ones with burnt out occlusio and seclusio pupillae and complicated cataracts were frowned upon in OPDs and were disposed in a routine fashion with an unsaid advice that nothing much could be done. I have some faint memories of candle wax drippings and snow balls in the dark and cold indirect ophthalmoscopy room of my post graduate institute. The posterior sub-tenon steroid injection seemed to be the panacea for all that fit into the diagnostic labels of intermediate and posterior uveitis.

The sub specialty has seen tremendous progress over the years, thanks to many dedicated ophthalmologists who took upon the challenge of pursuing this as their career and provided hopes to many of these otherwise neglected patients. My view of the disease too changed after I joined fellowship at Sankara Nethralaya Chennai and saw many of these patients actually gaining vision with treatment. Though it was not my practicing subspecialty, I got an opportunity of working on a Uvea project with Dr Jyotirmay Biswas (JB) during my fellowship days which later got published (Biswas J, Kazi MS, Agarwal VA, Alam MS, Therese KL. Polymerase chain reaction for Mycobacterium tuberculosis DNA detection from ocular fluids in patients with various types of choroiditis in a referral eye center in India. Indian J Ophthalmol. 2016;64(12):904-907. ). The experience was a real eye opener.

The chronic and recurring nature of the disease takes a toll on both the patients and their treating ophthalmologists and is a real test of patience and endurance for both. A plethora of new diagnostic tests and emergence of novel biological agents have led to both a clearer diagnosis and improved management. With newer and safer surgical techniques, the frontiers of expectations are being pushed further.

The present issue contains two review articles on molecular diagnosis in uveitis and different biological agents used as treatment options in non-infectious uveitis. There are interesting case reports on sympathetic ophthalmitis, intraocular lymphoma and the role of nested PCR and ELISA in toxoplasmic pan uveitis. There are two very interesting ophthalmic images covering acute retinal necrosis and VKH syndrome. The nutshell summarizes the clinical and investigative findings seen in different stages of VKH. This issue should be an enjoyable read. The next issue will be themed on vitreoretina. Kindly keep submitting articles and do provide your feedback for further improvement.

How to cite this article: Alam MS. The Grapes are no more Sour. Sci J Med & Vis Res Foun 2019; 37: 1

## Characterizing the Intraocular Inflammation will Save You the Day!

Prof. Amod Gupta

Emeritus professor  
Advanced Eye Centre  
Post Graduate Institute of  
Medical Education and research  
Chandigarh, India



Intraocular Inflammation of the eye can be broadly categorized into three categories-namely the infectious, the non-infectious and the masquerade. The main challenge of infectious inflammations is the early pin pointing of the offending microbial agent as highly effective antibiotics are available and once the infection heals the inflammation is cured forever. On the other hand, the challenge in non-infectious uveitis is to maintain a relapse-free quiescent eye with minimum ocular complications from the disease and the treatment. Timely diagnosis of underlying cancer presenting as masquerade inflammations can be life-saving for the patient. The infectious inflammations can be further subdivided into exogenous and metastatic or endogenous infections caused by bacteria or fungi. The exogenous infections follow either a penetrating trauma or incisional surgery, the most common being cataract surgery and are labelled as endophthalmitis. By and large, these infections do not pose a challenge in diagnosis due to a close temporal relationship with the preceding event except that differentiating a fungal from bacterial infection can be difficult and calls for an urgent intervention to obtain an intraocular fluid sample to establish a microbiological diagnosis and initiate appropriate treatment. It is the metastatic infections in the eye that often land at the doorsteps of a uveitis expert. Risk factors for these infections include septicemia, compromised immune system, immunosuppressive therapy for cancers, drug abusers, invasive surgical procedures on the GI or urogenital tract, indwelling catheters, long-term intravenous hyperalimentation, urinary tract infection or liver abscess. Patients who develop acute bacterial endogenous infections are often critically sick and still hospitalized when the infection sets up in the eye. If conscious, they may complain of a rather rapidly progressive loss of vision but in an unconscious patient, only a routine examination of the eyes can discover it. A detailed ocular examination of seriously sick patients is rarely if ever performed and the patient may discover blindness in one or both eyes on regaining consciousness.

Patients who present with endogenous fungal infections are most often ambulatory and walk into the clinic complaining of loss of vision, most often in one eye, weeks after their hospitalization or an invasive procedure. These patients generally do not volunteer a history of their systemic disease. A disastrous outcome awaits an ophthalmologist who misses the infectious cause of intraocular inflammation and inadvertently initiates corticosteroid therapy or worse still injects a depot steroid behind the eye or into the eye. Only a very high index of suspicion will save the day. Hazy ocular media (grade 3-4) and hypopyon, when the details of the interior of the eye cannot be made out on indirect ophthalmoscopy should raise a red flag as endogenous uveitis rarely if ever causes a dense media haze. All efforts should be made to obtain a history of visits or treatment in a healthcare facility in the recent past. Just to reiterate, in my experience, no patient with endogenous endophthalmitis has ever volunteered the history of treatment or hospitalization as they do not connect the two events. Occasionally, acute retinal necrosis may present with a severe media haze. In either case, I feel it prudent to obtain a vitreous sample using a small gauge (25/27) pars plana vitreous surgery for a complete microbiological work-up including a polymerase chain reaction to finding out the exact etiological agent. One must keep in mind that Behcet's disease may present with a recurrent mobile hypopyon with or without severe media haze. These patients do not warrant a vitreous biopsy that may only aggravate the inflammation. In all other inflammations of the posterior segment and the vitreous cavity, small gauge vitreous surgery can be safely performed for both diagnostic and therapeutic purposes. The masquerades typically occur at the extremes of age. A high index of suspicion is required as acute autoimmune uveitis is extremely uncommon at the extremes of age. Acute lymphoblastic leukaemia in young children may present with a hypopyon so can diffuse infiltrating retinoblastoma present with a pearly white deposit or hypopyon in the anterior chamber. They may require an anterior chamber tap to confirm the diagnosis by a cytopathologist. Old people beyond the age of 60-65 years may present with moderately severe vitreous haze and require a vitreous biopsy to confirm the diagnosis of primary vitreoretinal lymphoma.

The endogenous infectious uveitis may be caused by non-pyogenic microbes including parasites like toxoplasma gondii and Toxocara canis, DNA viruses like the Herpes group (HSV, VZV, CMV) or RNA viruses (Dengue, chikungunya, West Nile), bacteria (Tuberculosis; Syphilis). Starting these patients on corticosteroids without the appropriate antimicrobial agents can be disastrous, especially in patients with acute retinal necrosis (HSV and VZV) and toxoplasmosis.

While population-based data on the various infectious and non-infectious causes of uveitis is not available from anywhere in the world, the inference is generally drawn from the experience gained in referral institutes located in different parts of the world. At the least, all practising ophthalmologists need to become familiar with the clinical presentations of the infectious causes of endogenous uveitis in their geographic area as there is a heavy bias of aetiology in different parts of the world. While the world over, infectious uveitis accounts for less than 10-15% of all uveitis, in India, I have seen their number grow from 10% to nearly 30% of all uveitis cases seen in our tertiary care facility. This is by and large due to increasing recognition of viral infections and TB as a cause of uveitis. Toxoplasmosis accounts for nearly 8% of all uveitis in South India but less than 1% in North India tertiary care institutes. In a TB-endemic country like India, tuberculous uveitis, an autoimmune response driven by the presence of MTB either in the ocular tissues or elsewhere in the body is a major cause of uveitis and after several decades of "TB or no TB", its various phenotypes are presently recognized all across the TB-endemic as well as non-endemic regions of the world. The number of syphilitic uveitis is increasing all over the world, especially in men having sex with men. So is the greater recognition of Toxocara granulomas in young children.

The non-infectious endogenous uveitis is usually autoimmune or associated with systemic diseases like juvenile idiopathic arthritis-associated uveitis, bilateral anterior uveitis in children and young adolescents in tubulointerstitial nephritis and uveitis (TINU) syndrome, HLA B-27 associated acute anterior uveitis, Sarcoidosis, VKH disease, Sympathetic Ophthalmia, Behcet's disease and a host of the so-called white dot syndromes. All of these are well characterized and have clearly defined diagnostic criteria. Many of these are suspected to be driven by underlying as yet uncharacterized infections. The goal of the treatment in these patients is to achieve quiescence of the inflammation and prevention of recurrences with oral corticosteroids less than 10mg/day. Most of these autoimmune uveitis patients shall require long-term steroid-sparing immunosuppressive or immunomodulatory therapy which has been proven safe in prospective long-term studies. The commonest mistake I have encountered is a rapid tapering of corticosteroids once the inflammation subsides and the vision starts to improve, which invariably invites a recrudescence of the inflammation with much vigour and more difficulty to control. Nobody can predict complete remission of autoimmune uveitis. Recurrences of uveitis due to herpes viruses (anterior uveitis > ARN) and toxoplasmosis (retinochoroiditis) are not uncommon. As yet it is not possible to either predict or stop recurrences as these organisms remain latent throughout life and cannot be eradicated with the current therapeutic agents. On the other hand, MTB that remains latent in practically all the body tissues can be eliminated with the standard drug therapy and once treated remission of tuberculous uveitis can be obtained in nearly 85% of the patients.

How to cite this article: Gupta A, Characterizing the Intraocular Inflammation will Save You the Day! Sci J Med & Vis Res Foun 2019; 37 : 2-3

# Intraocular Lymphomas: Challenges in Diagnosis and Management

Arshee Ahmed<sup>1</sup>, Sudha K Ganesh<sup>2</sup>

1. Consultant, Dept of Uvea, Sankara Nethralaya, Chennai, Tamil Nadu, India.

2. Deputy Director, Dept of Uvea, Sankara Nethralaya, Chennai, Tamil Nadu, India.

Author for Correspondence:

**Arshee Ahmed**

Consultant, Dept of Uvea, Sankara Nethralaya, Chennai, Tamil Nadu, India.

drars@snmail.org

## Abstract:

The aim of this series is to report challenges faced in diagnosis of three cases of recurrent or atypical uveitis not responding to conventional treatment. A high index of suspicion aided by newer techniques like cytology, immunohistochemistry, flow cytometry is required for a prompt diagnosis of rare diseases like intraocular lymphomas.

**Keywords:** masquerade, cytology, immunohistochemistry

## Introduction:

Intraocular lymphomas (IOLs) are rare entities which constitute less than 1 percent of all intraocular malignancies. Literature on its proper classification remains sparse but are usually classified as those arising primarily in the eye (vitreoretinal - primary vitreoretinal lymphoma (PVRL) Primary Uveal Lymphoma (PUL) or in central nervous system (CNS) with subsequent ocular spread.<sup>[1]</sup>

IOLs are notorious for their varied presentations which usually mimic other forms of uveitis and hence, have been called “masquerades”.<sup>[2]</sup> This leads to a delay in diagnosis in majority of the patients, especially those who have primary IOLs. A high degree of clinical suspicion combined with the various newer techniques available for confirmation of diagnosis are essential for early diagnosis of this fatal intraocular malignancy.

Here we report our experience of diagnosing and managing three cases of IOL with varied presentations.

**Case 1:** A 65-year-old female presented with history of gradual decline in vision in both eyes since last 2 years. She was treated with multiple courses of oral and periocular steroids earlier. On examination, BCVA was 6/18, N18 in the right eye (OD) and counting fingers 50 cm in the left eye (OS). Anterior segment examination revealed a quiet anterior chamber (AC) with vitreous cells 2+ in both eyes. Fundus examination of both eyes revealed dense vitritis. Yellowish subretinal lesions were seen faintly at the posterior pole in OS. (Fig 1a)

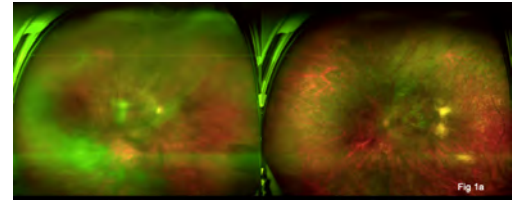


Fig 1a: Fundus photograph - Optos of both eyes of patient one at presentation showing vitreous haze in both eyes and yellow subretinal lesions at the posterior pole and along the inferior arcade in the left eye

Uveitis work up was non-contributory including negative Tuberculosis work up. Aqueous tap OS was done and subjected to polymerase chain reaction (PCR) analysis. The fluid tested positive for both genomes of M.Tb- IS6110 and MPB64. Anti-tubercular therapy and oral corticosteroids 1 mg/kg body weight were instituted. Four weeks later she complained of deterioration of vision in both eyes. BCVA had dropped to 6/45, N24 OD and to hand movements OS. Vitritis had worsened bilaterally with large confluent subretinal lesions noted at the posterior pole in OS. (Fig 1b)

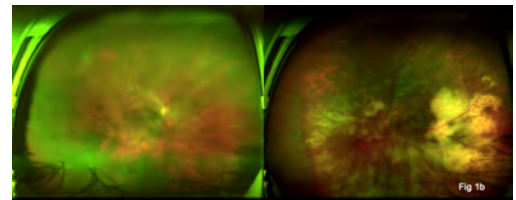


Fig 1b: Fundus photograph - Optos of both eyes of patient one after 4 weeks of antitubercular + steroid therapy showing extensive yellow subretinal lesions in the left eye compared to the first visit

Diagnostic 25 G vitrectomy was done. PCR testing was negative for both genomes of M.Tb, positive for toxoplasma B1gene and varicella zoster virus. Cytopathological testing was done next considering the gross dissimilarity in the PCR results from the aqueous and vitreous samples. Atypical lymphoid cells with necrotic background suggestive of PVRL were seen (Fig 1c)

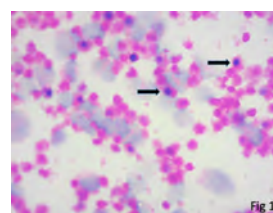


Fig 1c: Haematoxylin & eosin staining of the vitreous aspirate from the left eye showing atypical lymphoid cells (black arrows) with a necrotic background



MRI brain revealed extensive lesions in the right frontal, left temporal lobes, left internal capsule and left occipital cortex. Post-contrast study showed irregular & nodular enhancement. Findings were consistent with CNS lymphoma. The remaining vitreous aspirate was also subjected to PCR based RFLP for MYD88 L265P mutation which tested positive. She was advised to undergo external beam irradiation along with systemic chemotherapy.

**Case 2:** A 65-year-old male patient presented with sudden onset of pain, redness and loss of vision in his left eye for one month. The patient's past medical history revealed that he was a known case of systemic Non-Hodgkins lymphoma of the diffuse large B cell lymphoma (DLBCL) type and had completed 6 cycles of chemotherapy (the last cycle given 1 month before the onset of ocular complaints).

On examination BCVA was OD 6/6, N6 OD and perception of light OS. Both anterior segment and fundus examination of OD was within normal limits. Anterior segment OS revealed granulomatous keratic precipitates with AC cells 3+ (Fig 2a) Fundus examination revealed dense vitreous haze and vitreous cells 3+. Optic disc appeared pale. (Fig 2b) MRI brain was ordered next which revealed a T2 hyper intense signal in left intra-orbital optic nerve extending up to the apex. Post-contrast study showed no enhancement.

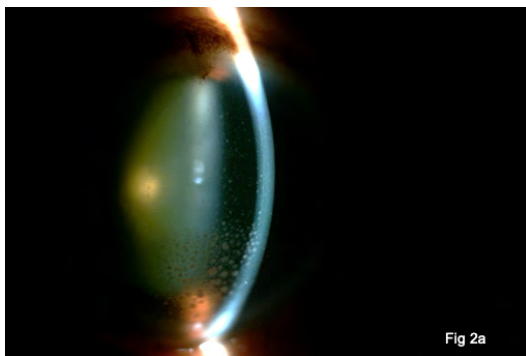


Fig 2 a: Slit lamp photograph of the left eye of patient two showing granulomatous keratic precipitates on the corneal endothelium

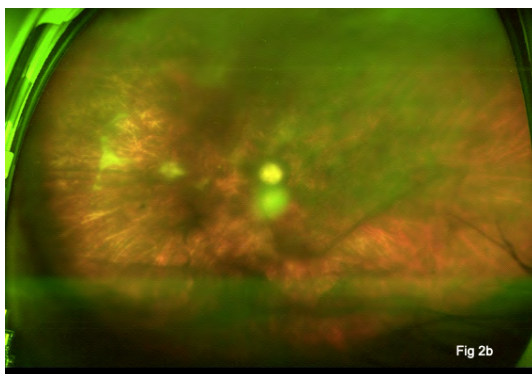


Fig 2 b: Fundus photograph-Optos of the left eye showing a vitreous floater, pale disc and chorioretinal atrophic patches in the nasal retina

Diagnostic 25-G vitrectomy was performed next. Cytopathological analysis revealed inflammatory cells with few lymphoid cells. No abnormal cells were noted on cytology and immunohistochemistry (IHC). One-month post vitrectomy the left eye was quiet. Fundus showed a pale disc with atrophic retina at the posterior pole. Close observation was advised.

**Case 3:** A 49-year-old male patient presented with sudden blurring of vision in OD for three weeks. He was diagnosed to have multifocal choroiditis and started on oral steroids locally. On presentation BCVA OD was 6/15, N 36, OS 6/6, N6. Fundus examination OD revealed a yellow subretinal lesion at the macula with multiple sub retinal yellowish precipitates around it (Fig 3a).

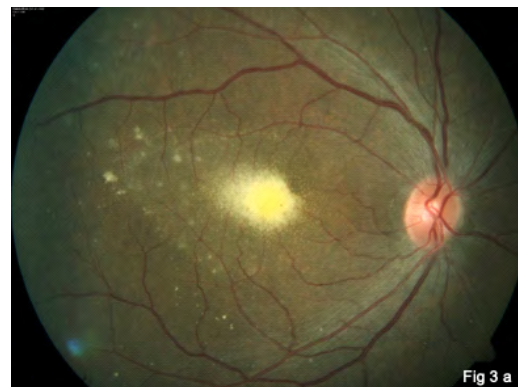

Fig 3 a: Fundus photograph -posterior pole- of the right eye of patient three showing a yellowish subretinal lesion at the macula with surrounding yellowish precipitates

Ancillary investigations like FAF, FFA, and OCT and a complete uveitis work up including tests for TB were inconclusive. A presumed diagnosis of unilateral acute idiopathic maculopathy was considered and oral steroids were continued. The macular lesion showed resolution and scarring in one month of steroid therapy (Fig 3b).

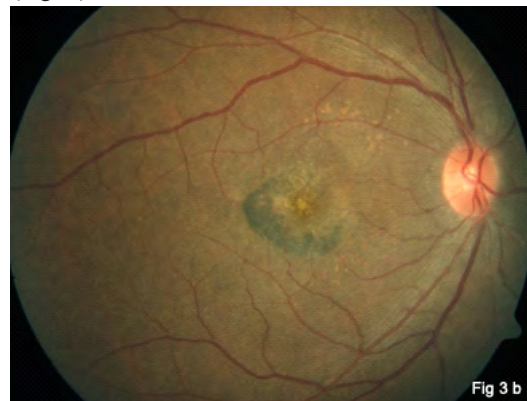

Fig 3b: Scarred lesion at the macula after 1 month

**Table 1:** Key findings of various investigations in Intraocular Lymphomas

Investigative modality	Key findings
Cytology	pleomorphic, medium-large sized cells with minimal cytoplasm, indented or folded nucleoli, prominent nucleoli Background of necrotic T cells
Immunohistochemistry (IHC)	Specific B cell markers like CD 20+,CD 79a+,BCL-2, MUM1/IRF4+,BCL 6+
Flow cytometry	restricted expression of $\kappa$ : $\lambda$ light chain $\kappa$ : $\lambda$ ratio >3 or <0.6
Molecular	IgH gene rearrangements, Bcl-2 proto-oncogene translocations
Cytokine profile analysis	elevated IL 10 levels in vit aspirates IL 10: IL 6 ratio > 1

3 weeks later the patient had a seizure. MRI showed a space occupying lesion in the fronto-parietal lobe and cingulate gyrus. He underwent surgical debulking, and biopsy material was subjected to various studies. IHC studies showed positive reaction to B cell markers CD20, CD79a, Bcl-2, Bcl-6. Bone marrow aspiration showed a hypercellular marrow, lymphocytes 3%, blasts 2%. Considering histology and IHC reactions a diagnosis of Primary CNS lymphoma of diffuse B cell phenotype with aggressive histology was made. The patient was started on systemic chemotherapy and radiotherapy but succumbed to the disease within a month of diagnosis. In retrospect we concluded that, the ocular findings were that of IOL masquerading as a macular lesion which responded well to systemic steroids.

**Discussion:** Intraocular lymphomas are rare lymphoproliferative disorders, which are known to present in varied ways. Anterior segment and posterior segment findings can range from keratic precipitates, AC reaction, pseudohypopyon (rarely), vitreous haze, vitreous infiltration by lymphoma cells in various patterns, creamy deep retinal/ sub-RPE infiltrates (as in patients one and three), exudative retinal detachment, RPE atrophy with subretinal fibrosis, and rarely, disciform scarring at the macula. Secondary IOLs are known to present with granulomatous anterior uveitis (patient two).<sup>[3]</sup>

Diagnosis solely based on clinical features is difficult in most cases as demonstrated by all three cases presented in this series. Here we would like to highlight the role of multi-targeted evaluation of the ocular samples obtained by aqueous/ vitreous biopsy by cytopathology, IHC, flow cytometry and cytokine analysis.

These have shown to be very effective in aiding a diagnosis of IOL in such cases. The key findings of all these techniques have been highlighted in table one.<sup>[4]</sup>

Recently, Cani K et al have demonstrated the role of next generation sequencing to detect MYD88 Gain of Function mutations which are highly specific for PVRL.<sup>[5]</sup>

We were also able to identify this mutation in patient one which confirmed the diagnosis. Although cytology and IHC were both negative in patient two, a diagnosis of IOL was still considered as both prior chemotherapy and steroid use could have affected the vitreous biopsy result.

A high degree of clinical suspicion is necessary in such cases for early detection of IOLs aided by appropriate ancillary diagnostic techniques including MRI brain. It is imperative for the treating ophthalmologist to be aware of IOL as a differential in such cases and rely on a step wise approach specially in a patient of suggestive age with a history of recurrent, intractable or atypical intermediate or posterior uveitis.

#### References:

1. Venkatesh R, Bavaharan R, Mahendradas P, Yadav NK. Primary vitreoretinal lymphoma: prevalence, impact and management challenges. Clin Ophthalmol. 2019 Feb 14;13:353-364
2. D. Kalogeropoulos, Vartholomatos G, Mitra A et al. Primary vitreoretinal lymphoma. Saudi J Ophthalmol 2019;33(1): 66-80
3. Llorenç V, Fuster C, Alba-Linero C et al. Clinical features of primary and systemic metastatic intraocular lymphomas in Spanish patients. J Ophthalmol. 2019 Oct 16;2019: 6327041
4. Coupland SE, Chan CC, Smith J. Pathophysiology of retinal lymphoma. Ocul Immunol Inflamm. 2009;17:227-37
5. Cani AK, Solomon M, Hovelson DH et al. Comprehensive genomic profiling of orbital and ocular adnexal lymphomas identifies frequent alterations in MYD88 and chromatin modifiers: new routes to targeted therapies.

How to cite this article: Ahmed A, Ganesh SK. Intraocular Lymphomas: Challenges In Diagnosis And Management. Sci J Med & Vis Res Foun 2019; 37 : 4-6

# Molecular Diagnosis of Infectious Uveitis: An Update

A R Anand<sup>1</sup>, Jyotirmay Biswas<sup>2</sup>

1. L & T Microbiology  
Research Centre, Medical  
Research Foundation, Chennai,  
India

2. Director, Department of  
Uvea and Ocular Pathology,  
Medical Research Foundation,  
Chennai, India.

Author for Correspondence:

**A R Anand**

L & T Microbiology Research  
Centre, Medical Research  
Foundation, Chennai, India

e-mail: dranand@snmail.org

## Abstract:

Uveitis is a sight-threatening intraocular inflammatory disorder with an aetiology that could be infectious or non-infectious. In addition to the herpesviruses, including herpes simplex virus types (HSV)-1 and -2, varicella-zoster (VZV), and cytomegalovirus (CMV), the bacterium *Mycobacterium tuberculosis* and the parasite *Toxoplasma gondii* are the most common known causes of infectious uveitis in our setting. However, a clinical diagnosis is often challenging due to overlapping clinical findings among non-infectious and infectious uveitis, and among uveitis caused by different infectious agents. With conventional microbiological techniques lacking sensitivity in laboratory diagnosis of uveitis, molecular diagnostic techniques have come to the rescue in recent years. The diagnosis of uveitis in clinical practice has been dramatically altered by the application of molecular investigations, particularly polymerase chain reaction (PCR). Several variations of conventional PCR such as Multiplex PCR, Real-time PCR, comprehensive PCR systems (combination of multiplex PCR and real-time PCR) and broad-range PCR techniques (that can detect of any bacterial or fungal genomic DNA in the sample) that have been evaluated in the diagnosis of uveitis. In addition, next-generation sequencing (NGS) techniques, which allows the comprehensive analysis of all bacterial/fungal/viral genomes as well as their abundance, are recently being evaluated in intraocular samples from uveitis patients. In the present review, we provide an up-to-date overview of these molecular techniques and their tremendous potential not only to provide an prompt aetiological diagnosis, but also identify new clinical entities of uveitis, thereby facilitating appropriate therapy.

**Keywords:** Uveitis; molecular diagnosis; PCR; NGS

Uveitis is the inflammation of the uvea, the pigmented vascular middle layer of the eye, which consists of the iris, ciliary body and choroid. It is an important cause of ocular morbidity and vision loss, worldwide<sup>[1]</sup>.

The prevalence of uveitis shows variation geographically with rough estimates of around 38 per 100,000 in France, 200 per 100,000 in the US, and 730 per 100,000 in India<sup>[2]</sup>.

Uveitis, the fifth commonest cause of visual loss in the developed world, can cause varying degrees of visual loss. Visual morbidity due to uveitis was not evaluated in India, though experts feel that it will be higher than the developed countries. The aetiology of uveitis is often unclear, and only approximately 17% of uveitis cases are caused by an infectious agent that is ultimately identified<sup>[3]</sup>. *Mycobacterium tuberculosis*, *Toxoplasma gondii* and herpesviruses, including herpes simplex virus types 1 and 2 (HSV-1 and HSV-2), varicella-zoster (VZV), and cytomegalovirus (CMV), are the most common known causes of infectious uveitis, although other bacteria, fungi, viruses and parasites may rarely also be involved.

Arriving at a diagnosis of uveitis only based on the patient's history and clinical findings is often challenging. This is because of overlapping clinical findings among intraocular inflammation caused by different infectious agents, and also with observations made for noninfectious causes of uveitis, such as those caused by autoimmune diseases and trauma<sup>[3]</sup>. Moreover, many non-inflammatory ocular disorders may present as intraocular inflammatory disease and may be diagnosed and treated as uveitis<sup>[3, 4]</sup>. This uncertainty may delay the onset of potentially effective treatment. Hence laboratory investigations are critical to facilitate a aetiological diagnosis. Conventional microbiological investigations in the diagnosis of uveitis lack sensitivity due to various factors including low pathogen load and small sample volume that can be safely obtained from the eye. The urgency to develop better diagnostics for uveitis has also been necessitated by the recent cases of ocular inflammation in patients with Ebola virus<sup>[5]</sup>, and Zika virus<sup>[6]</sup>, that suggest the role of the eye as a potential source of such infections. Hence it is critical that more sensitive, specific, and comprehensive approaches are developed to efficiently diagnose ocular infections. For these reasons, there is considerable interest in molecular detection of uveitis-associated pathogens directly in intraocular fluids of suspected uveitis cases.

## Molecular techniques in diagnosis of infectious uveitis

Significant advances in molecular technologies for infectious disease diagnosis have been made in the last decade.

The diagnosis of uveitis in clinical practice has been revolutionized by the application of molecular techniques, particularly polymerase chain reaction (PCR)<sup>[7-10]</sup>. Recently, variations of PCR as well as newer molecular techniques are being evaluated. These new molecular diagnostic tests are highly sensitive, specific, and rapid, requiring very small volumes of sample. These tests have not only increased the frequency of uveitis cases with aetiological diagnosis, but also resulted in the identification of new aetiological agents causing uveitis.

#### **Collection of sample for molecular detection :**

The most commonly used specimen for diagnosis of uveitis is the aqueous humor (AH) sample (150–300 µl), that is collected aseptically in a tuberculin syringe with a 30-gauge needle under aseptic precautions as an outpatient department (OPD) procedure, though vitreous fluids can also be collected during pars plana vitrectomy and fine needle aspiration biopsy. Following collection, specimens are immediately transported to the laboratory, transferred onto pre-sterilized microcentrifuge tube and stored at – 20 °C for DNA extraction.

#### **Polymerase Chain Reaction (PCR)-based assays**

PCR is a technique whereby theoretically a single or a few copies of a specific piece of DNA are amplified across several orders of magnitude, generating millions of copies of a that specific DNA fragment, which in turn can be analysed easily. Polymerase chain reaction (PCR) analysis of ocular fluid samples has allowed an early, accurate, and rapid detection of small quantities of pathogen-derived DNA or RNA in the uveal tract. In the past decade, PCR-based assays have been used extensively to discriminate infectious from noninfectious causes of intraocular inflammation and for identification of the causative agents. We and others have shown to be highly sensitive and specific test for detecting CMV, HSV, VZV, *Toxoplasma gondii* as well as *Mycobacterium tuberculosis*<sup>[11-13,9,14-21]</sup>.

#### **PCR protocol**

Once the DNA is extracted and purified generally using commercial DNA isolation kits, PCR can be set-up by adding the following basic components in a reaction tube (i) a DNA template extracted from the sample (ii) at least two primer pairs (the sense and antisense strands of the DNA target) (iii) Taq DNA polymerase (iv) individual nucleotides (dNTPs) and buffers. The PCR cycle consists of a series of 20–40 repeated thermal cycles, with each cycle commonly consisting of two to three distinct temperature step- denaturation, annealing and extension. Following completion of the PCR, agarose gel electrophoresis is used to separate the PCR products and check whether the PCR amplified the targeted DNA fragment with the aid of a standard DNA molecular weight marker.

#### **Conventional PCR**

The most widely used molecular diagnostic panel for infections in uveitis includes individual pathogen-directed polymerase chain reactions (PCRs) for CMV, HSV, VZV, *Toxoplasma gondii* and *M.tuberculosis*. Several studies, including ours, have evaluated single-target (uniplex) reactions performed by traditional PCR methods<sup>[12,21,22]</sup>. In a recent study, our group studied 100 cases of suspected uveitis<sup>[23]</sup>, where uniplex PCR analysis was able to confirm the clinical diagnosis in almost 70% of the cases.

#### **Multiplex PCR**

The most characteristic feature of multiplex PCR is its ability to measure multiple target genomic DNAs in one assay, unlike a classic uniplex PCR which can measure only one target genomic DNA. Therefore, specific genomic DNA from different viruses, bacteria, parasites and fungi can be measured simultaneously in a small sample volume in a single closed-tube reaction, which is particularly important for intraocular fluid samples, such as aqueous humor and vitreous humor. Multiplex PCR has been evaluated both conventionally (qualitative) or in a real-time mode (quantitative) to diagnose infectious uveitis<sup>[13, 24, 25]</sup>. A multiplex PCR assay for rapid detection and identification of herpes simplex viruses 1 and 2 (HSV-1 and HSV-2), varicella-zoster virus (VZV), cytomegalovirus (CMV), and *T. gondii* is one of the most common molecular assays in the diagnosis of infectious uveitis<sup>[13]</sup>.

#### **Real-time PCR**

A real-time PCR, also known as quantitative polymerase chain reaction (qPCR), is a variation of PCR, where the amplification of a targeted DNA molecule during the PCR is monitored in real-time, and not on its termination, as in conventional PCR. Therefore real-time PCR can be used to quantify the number of pathogen DNA copies in the sample. Fluorescent intercalating dyes or DNA probes labelled with a fluorescent reporter are used to measure the number of DNA copies in real-time. A few recent studies, including ours, have successfully evaluated real-time PCR targeting individual pathogens to diagnose uveitis<sup>[14, 26, 18, 19, 25]</sup>. The quantification of copy numbers by real-time PCR will not only help in determining pathogen load, but also to differentiate true- positives and false positives. A high copy number obtained in real-time PCR assay generally indicates active microbial replication in the eye.

#### **Comprehensive PCR systems**

PCR-based assays have been used to differentiate infectious from noninfectious causes of intraocular inflammation and for identification of the causative agent.

However, most of these tests are singleplex or multiplex reactions performed by traditional PCR methods that rely on post-PCR handling for detection and identification, increasing turnaround time and risk of carryover contamination. Comprehensive PCR systems consisting of a combination of multiplex PCR and real-time PCR have recently been developed for diagnosis of infectious uveitis<sup>[11, 15, 27]</sup>. One study<sup>[11]</sup> combined multiplex PCR was designed to detect genomic DNA of all eight human herpes viruses (HHV 1-8), toxoplasma, parvovirus B19, BK virus, and JC virus (JCV). Any result positive by multiplex PCR was followed by quantitative real-time PCR to measure the copy number of the genome in the sample and thus confirm its pathogenic role. Recently another multiplex- real time assay<sup>[15]</sup> was designed to detect the most common uveitis pathogens using real-time PCR technology, all in one reaction. The authors evaluated multiplex real-time PCR assay coupled with high-resolution melting (HRM) for rapid detection and identification of HSV-1, HSV-2, VZV, CMV and *T. gondii* and found the assay to be highly sensitive. This assay led to the rapid, sensitive, and accurate detection and identification of the most common causes of infectious uveitis, making prompt pathogen information-based intervention possible.

#### **Broadrange PCR**

Broad-range PCR techniques involve the detection of any bacterial or fungal genomic DNA in the sample. Both bacterial ribosomal DNA genes (16S rDNA) or fungal ribosomal DNA genes (18S or 28S rDNA) have been previously used as targets for qualitative broad-range PCR performed with ocular fluids of patients with infectious endophthalmitis and uveitis<sup>[28, 29, 23, 30]</sup>. Broad-range PCR techniques use primers and probes that target regions in the DNA that are conserved among all bacteria or all fungi. These PCRs detect the presence of bacterial or fungal infection in the eye. The identification of the bacterium or fungus can be done by sequencing the PCR products. Recently real-time PCR primers and probes for bacterial 16S rDNA and fungal 18S/28S rDNA amplifications have been evaluated<sup>[31, 32]</sup>. This has made it possible to perform quantitative measurements on the copy numbers, which may be helpful in differentiating contaminating DNA from pathogenic DNA.

#### **Multiplex solid-phase PCR strip kit**

Recently, a new comprehensive PCR strip kit (a multiplex solid-phase PCR strip kit) is being evaluated in the diagnosis of infectious uveitis<sup>[33]</sup>. This PCR strip consists of a 12-tube multiplex PCR strip coated with primers and probes targeting the genomes for 24 common pathogens of various infectious eye diseases. The main advantage of this assay is that all the common ocular pathogens can be detected in one assay that takes only a few hours using a simple easy-to-use PCR assay.

#### **Metagenomic gene sequencing (MGS):**

A significant percentage of all presumed intraocular infections, including uveitis fail to have a pathogen identified. Hence newer molecular techniques such as metagenomic gene sequencing (MGS) can be of great value in the diagnosis of infectious uveitis. MGS allows scientists to comprehensively analyze genes from all organisms present in a given clinical sample. This method has enabled researchers to evaluate both bacterial/fungal/viral diversity as well as their abundance in various environments. MGS has tremendous potential to improve diagnostic yield as it is free of bias and can theoretically detect all pathogens in a clinical sample. There have been two recent studies, that have used two variations of MGS in the diagnosis of infectious uveitis. In the first study<sup>[34]</sup>, Doan et al demonstrated that unbiased RNA sequencing (RNA-seq) of intraocular samples was sensitive in detecting fungi, parasites, DNA and RNA viruses in uveitis patients. In this study of 6 cases, the authors found a virus not in the common panel for uveitis diagnosis - an RNA virus Rubella virus in a case of uveitis. However, one obvious drawback of this technique is that optimal RNA sequencing requires proper specimen handling, including either flash-freezing or immediate placement of the specimen on dry ice. Another study<sup>[35]</sup> used metagenomic DNA sequencing (DNA-seq) to bypass this challenge, as DNA is more tolerant of varying temperatures. However, a major drawback of DNA-seq is that it cannot detect RNA viruses (e.g., rubella). In both the MGS studies, the results of MGS was confirmed with pathogen-directed PCRs, indicating the accuracy of these techniques. An added advantage of metagenomic deep sequencing is the potential to apply sequence information to infer the phenotypic behavior of the pathogen. In fact, Doan et al compared samples in which CMV sequences were adequately recovered for the UL54 and UL97 genes, coding for the DNA polymerase and phosphotransferase respectively, and compared with a CMV antiviral drug resistance database. Of the 7 samples analyzed, 3 had mutations in UL97 (phosphotransferase) that confer ganciclovir and valganciclovir resistance.

#### **Conclusion**

In summary, molecular methods, especially PCR assays performed with small amounts of intraocular samples provide a prompt, sensitive, and specific molecular diagnosis of pathogenic microorganisms associated with uveitis. Application of newer technologies like metagenomic sequencing will help to establish new aetiologies and clinical entities of uveitis caused by infectious microorganisms. Based on the success of recent pilot studies on NGS, a practical

diagnostic approach in uveitis could be to test for a limited panel of infectious agents by routine pathogen-specific uniplex/multiplex PCR. If these are negative, the sample could be tested by metagenomic DNA and RNA sequencing for uncommon agents. This approach will not only complement the current diagnostic paradigm in ophthalmology but also allow for a more comprehensive characterization of the aetiology of infectious uveitis.

#### References:

1. Suttorp-Schulten MS, Rothova A: The possible impact of uveitis in blindness: a literature survey. *Br J Ophthalmol.* 1996, 80:844-8.
2. Dandona L, Dandona R, John RK, McCarty CA, Rao GN: Population based assessment of uveitis in an urban population in southern India. *Br J Ophthalmol.* 2000, 84:706-9.
3. Rodriguez A, Calonge M, Pedroza-Seres M, Akova YA, Messmer EM, D'Amico DJ, Foster CS: Referral patterns of uveitis in a tertiary eye care center. *Arch Ophthalmol.* 1996, 114:593-9.
4. Rothova A, Ooijman F, Kerkhoff F, Van Der Lelij A, Lokhorst HM: Uveitis masquerade syndromes. *Ophthalmology* 2001, 108:386-99.
5. Varkey JB, Shantha JG, Crozier I, Kraft CS, Lyon GM, Mehta AK, Kumar G, Smith JR, Kainulainen MH, Whitmer S, Stroher U, Uyeki TM, Ribner BS, Yeh S: Persistence of Ebola Virus in Ocular Fluid during Convalescence. *New Engl J Med.* 2015, 372:2423-7.
6. de Paula Freitas B, de Oliveira Dias JR, Prazeres J, Sacramento GA, Ko AI, Maia M, Belfort R, Jr.: Ocular Findings in Infants With Microcephaly Associated With Presumed Zika Virus Congenital Infection in Salvador, Brazil. *JAMA Ophthalmol* 2016, 134:529-35.
7. Harper TW, Miller D, Schiffman JC, Davis JL: Polymerase chain reaction analysis of aqueous and vitreous specimens in the diagnosis of posterior segment infectious uveitis. *Am J Ophthalmol.* 2009, 147:140-7 e2.
8. Rothova A, de Boer JH, Ten Dam-van Loon NH, Postma G, de Visser L, Zuurveen SJ, Schuller M, Weersink AJ, van Loon AM, de Groot-Mijnes JD: Usefulness of aqueous humor analysis for the diagnosis of posterior uveitis. *Ophthalmology* 2008, 115:306-11.
9. de Boer JH, Verhagen C, Bruinenberg M, Rothova A, de Jong PT, Baarsma GS, Van der Lelij A, Ooyman FM, Bollemeijer JG, Derhaag PJ, Kijlstra A: Serologic and polymerase chain reaction analysis of intraocular fluids in the diagnosis of infectious uveitis. *Am J Ophthalmol.* 1996, 121:650-8.
10. De Groot-Mijnes JD, Rothova A, Van Loon AM, Schuller M, Ten Dam-Van Loon NH, De Boer JH, Schuurman R, Weersink AJ: Polymerase chain reaction and Goldmann-Witmer coefficient analysis are complimentary for the diagnosis of infectious uveitis. *Am J Ophthalmol.* 2006, 141:313-8.
11. Bispo PJM, Davoudi S, Sahn ML, Ren A, Miller J, Romano J, Sobrin L, Gilmore MS: Rapid Detection and Identification of Uveitis Pathogens by Qualitative Multiplex Real-Time PCR. *Investigative ophthalmology & visual science Invest Ophthalmol Vis Sci.* 2018, 59:582-9.
12. Biswas J, Kazi MS, Agarwal VA, Alam MS, Therese KL: Polymerase chain reaction for Mycobacterium tuberculosis DNA detection from ocular fluids in patients with various types of choroiditis in a referral eye center in India. *Ind J Ophthalmol.* 2016, 64:904-7.
13. Dabil H, Boley ML, Schmitz TM, Van Gelder RN: Validation of a diagnostic multiplex polymerase chain reaction assay for infectious posterior uveitis. *Arch Ophthalmol.* 2001, 119:1315-22.
14. Errera MH, Goldschmidt P, Batellier L, Degorge S, Heron E, Laroche L, Sahel JA, Westcott M, Chaumeil C: Real-time polymerase chain reaction and intraocular antibody production for the diagnosis of viral versus toxoplasmic infectious posterior uveitis. *Graefes Arch Clin Exp Ophthalmol.* 2011, 249:1837-46.
15. Kumar A, Singh MP, Bansal R, Gupta A, Ram J, Ratho RK: Development and evaluation of multiplex real-time PCR for diagnosis of HSV-1, VZV, CMV, and Toxoplasma gondii in patients with infectious uveitis. *Diag Micr Infec Dis.* 2017, 89:191-6.
16. Mahalakshmi B, Therese KL, Madhavan HN, Biswas J: Diagnostic value of specific local antibody production and nucleic acid amplification technique-nested polymerase chain reaction (nPCR) in clinically suspected ocular toxoplasmosis. *Ocul Immunol Inflamm.* 2006, 14:105-12.
17. Nandi K, Ranjan P, Therese L, Biswas J: Polymerase chain reaction in intraocular inflammation. *Open ophthalmol J* 2008, 2:141-5.
18. Rao VG, Janani MK, Biswas J: Real-time polymerase chain reaction in recurrent cytomegalovirus anterior uveitis. *Am J Ophthalmol* 2019, 15:100470.
19. Selvaraj JR, Sudharshan S, Therese LK, Janani MK, Selvamuthu P, Rewri P, Biswas J: Real-time polymerase chain reaction for diagnosis and management of HIV-induced uveitis. *Ind J Ophthalmol.* 2018, 66:1634-6.

20. Shah A, Biswas J: Cytopathology and Polymerase Chain Reaction of Vitreous Fluid in Tubercular Intermediate Uveitis. *Ocul Immunol Inflamm.* 2020;1-3.
21. Shylaja R, Vimalin Jeyalatha M, Malathi J, Biswas J, Madhavan HN: Standardisation and application of polymerase chain reaction for detection of Lru A and Lru B gene of *Leptospira interrogans* in aqueous humors of uveitic patients. *Ocul Immunol Inflamm.* 2011, 19:363-6.
22. Siqueira RC, Cunha A, Orefice F, Campos WR, Figueiredo LT: PCR with the aqueous humor, blood leukocytes and vitreous of patients affected by cytomegalovirus retinitis and immune recovery uveitis. *Ophthalmologica* 2004, 218:43-8.
23. Kharel Sitaula R, Janani MK, Madhavan HN, Biswas J: Outcome of polymerase chain reaction (PCR) analysis in 100 suspected cases of infectious uveitis. *J Ophthalmic Inflamm Infect.* 2018, 8:2.
24. Sugita S, Ogawa M, Inoue S, Shimizu N, Mochizuki M: Diagnosis of ocular toxoplasmosis by two polymerase chain reaction (PCR) examinations: qualitative multiplex and quantitative real-time. *Jpn J Ophthalmol.* 2011, 55:495-501.
25. Sugita S, Shimizu N, Watanabe K, Mizukami M, Morio T, Sugamoto Y, Mochizuki M: Use of multiplex PCR and real-time PCR to detect human herpes virus genome in ocular fluids of patients with uveitis. *Br J Ophthalmol.* 2008, 92:928-32.
26. Gondchawar A, Biswas J, Murali S, Eawaran LM: A case of herpes simplex keratouveitis diagnosed by real time polymerase chain reaction. *Ind J Ophthalmol.* 2015, 63:854-5.
27. Sugita S, Ogawa M, Shimizu N, Morio T, Ohguro N, Nakai K, Maruyama K, Nagata K, Takeda A, Usui Y, Sonoda KH, Takeuchi M, Mochizuki M: Use of a comprehensive polymerase chain reaction system for diagnosis of ocular infectious diseases. *Ophthalmology* 2013, 120:1761-8.
28. Anand A, Madhavan H, Neelam V, Lily T: Use of polymerase chain reaction in the diagnosis of fungal endophthalmitis. *Ophthalmology* 2001, 108:326-30.
29. Anand AR, Madhavan HN, Therese KL: Use of polymerase chain reaction (PCR) and DNA probe hybridization to determine the Gram reaction of the infecting bacterium in the intraocular fluids of patients with endophthalmitis. *J Infection* 2000, 41:221-6.
30. Therese KL, Anand AR, Madhavan HN: Polymerase chain reaction in the diagnosis of bacterial endophthalmitis. *Br J Ophthalmol.* 1998, 82:1078-82.
31. Ogawa M, Sugita S, Shimizu N, Watanabe K, Nakagawa I, Mochizuki M: Broad-range real-time PCR assay for detection of bacterial DNA in ocular samples from infectious endophthalmitis. *Jpn J Ophthalmol.* 2012, 56:529-35.
32. Sugita S, Kamoi K, Ogawa M, Watanabe K, Shimizu N, Mochizuki M: Detection of *Candida* and *Aspergillus* species DNA using broad-range real-time PCR for fungal endophthalmitis. *Graefes Arch Clin Exp Ophthalmol.* 2012, 250:391-8.
33. Nakano S, Sugita S, Tomaru Y, Hono A, Nakamuro T, Kubota T, Takase H, Mochizuki M, Takahashi M, Shimizu N: Establishment of Multiplex Solid-Phase Strip PCR Test for Detection of 24 Ocular Infectious Disease Pathogens. *Invest Ophthalmol Vis Sci.* 2017, 58:1553-9.
34. Doan T, Wilson MR, Crawford ED, Chow ED, Khan LM, Knopp KA, O'Donovan BD, Xia D, Hacker JK, Stewart JM, Gonzales JA, Acharya NR, DeRisi JL: Illuminating uveitis: metagenomic deep sequencing identifies common and rare pathogens. *Genome medicine* 2016, 8:90.
35. Doan T, Acharya NR, Pinsky BA, Sahoo MK, Chow ED, Banaei N, Budvytiene I, Cevallos V, Zhong L, Zhou Z, Lietman TM, DeRisi JL: Metagenomic DNA Sequencing for the Diagnosis of Intraocular Infections. *Ophthalmology* 2017, 124:1247-8.

How to cite this article: Anand AR, Biswas J. Molecular Diagnosis of Infectious Uveitis: An Update. *Sci J Med & Vis Res Foun* 2019; 37 : 7-11

# Biologics: A New Paradigm in the Management of Noninfectious Uveitis

Samantha Prabakaran<sup>1</sup> Ricci Allen<sup>1</sup> Amravi Shah<sup>2</sup> Jyotirmay Biswas<sup>2</sup>.

1. L & T Microbiology  
Research Centre, Medical  
Research Foundation, Chennai,  
India

2. Director, Department of  
Uvea and Ocular Pathology,  
Medical Research Foundation,  
Chennai, India.

Author for Correspondence:

**Jyotirmay Biswas**

Director

Department of Uvea and Ocular  
Pathology

Medical Research Foundation,  
Sankara Nethralaya

18 college Road, Chennai  
600006

drjb@snmail.org

## Abstract:

Uveitis is one of the leading causes of visual impairment and legal blindness in both developed and developing countries. The first line of treatment for idiopathic uveitis is corticosteroids, which often cause serious local and systemic effects. Recently, immune and inflammatory pathways at the cellular level have been recognized in the pathogenesis of disorders causing uveitis with the goal to prevent inflammation and halt disease progression in the tissues to prevent further tissue damage. Biologics can be considered as treatment of choice in noninfectious uveitis when conventional immunosuppressive therapy has failed or has been poorly tolerated, or in acute vision-threatening non-infectious uveitis when corticosteroid therapy is contraindicated and the onset of immunomodulatory agents will be delayed.

Adamulibab marketed as Humira is the only biologic that has so far been approved by the FDA for use in Uveitis. There are currently three uveitis orphan drugs have been approved by the FDA.

**Keywords:** uveitis, biologics, idiopathic uveitis, non-infectious uveitis, tnfi inhibitors

## Introduction:

Uveitis is one of the leading causes of visual impairment and legal blindness in both developed and developing countries<sup>[1, 2]</sup>. This article is on idiopathic uveitis, which has no recognizable cause<sup>[3]</sup>. The focus of the paper is on the management of idiopathic uveitis using biologics that target the immune and inflammatory pathways at the cellular level.

**Etiology:** Uveitis may be secondary to infectious agents such as Tuberculosis, Toxoplasmosis, Cytomegalovirus, Herpes Simplex, Herpes Zoster, Treponema Pallidum and Borrelia burgdorferi or as an ocular manifestation of systemic conditions such as spondyloarthritides, Adamantiades–Behcet's disease (ABD), systemic lupus erythematosus, multiple sclerosis, and sarcoidosis. Uveitis secondary to infection is managed by treating the cause<sup>[4]</sup> or managing the underlying systemic disease.

## Treatment of Idiopathic Uveitis:

Uveitis may also be idiopathic<sup>[3]</sup> with no recognizable cause. The first line of treatment of idiopathic uveitis is with either local or systemic corticosteroids<sup>[5]</sup>. Steroids may be given locally in the form of drops, periocular injections, intraocular implants, or via a systemic route<sup>[6]</sup>. Long term steroid treatment, irrespective of the route, carries serious local adverse effects such as cataract and glaucoma, and systemic such as hypertension and glucose intolerance<sup>[7]</sup>. Steroid sparing drugs known as immunomodulators are used to avoid these toxic effects. Immunomodulator therapy (IMT) includes the antimetabolites namely methotrexate, azathioprine, and mycophenolate mofetil; calcineurin inhibitors, such as cyclosporine, tacrolimus, and sirolimus; alkylating agents like cyclophosphamide and chlorambucil<sup>[8]</sup>. IMT requires additional patient education regarding the potential side effects, need for specific vaccinations, and baseline and follow up laboratory and organ function tests.

More recently, immune and inflammatory pathways at the cellular level have been recognized in the pathogenesis of disorders such as Juvenile Rheumatoid arthritis and Behcet's Disease<sup>[9]</sup>. Specific mediators involved in the pathogenesis have been identified, resulting in development of drugs that specifically target and block the mediators and the associated inflammatory pathways at the cellular level<sup>[10]</sup>. The goal of this focused blockade of the local inflammatory processes is to avoid symptoms and also to suppress the progression to the tissues and preserve function<sup>[5]</sup>. Such methods have been quite successful in auto-immune rheumatological illnesses, encouraging the study and discovery of immune pathways in other immune related illnesses such as idiopathic uveitis. The agents for use in uveitis are expanding, with great expectation for ophthalmologists caring for patients suffering from uveitis, and immense optimism for the patient afflicted with uveitis.

Agents that target the mechanisms at the cellular level of inflammation are made from complex molecules and components of living microorganisms, plants, or animal cells. Many use recombinant DNA technology and hence are called biologics, rather than drugs, which are made from chemicals.



Depending on their form, monoclonal antibodies, cytokines, cytokine antagonists, or receptors, biologics can interfere with the inflammatory process and immune reaction<sup>[7]</sup>. Biologic therapy targets specific cells, receptors, and mediators that participate in the immune response, such as Tumour Necrosis Factor  $\alpha$ , (TNF- $\alpha$ ), anti-interleukin, and anti-interleukin receptor<sup>[11]</sup>. Targeted blocking of immune-mediated inflammatory pathways can suppress the unwanted immune effector response, which will decrease the inflammatory activity taking place in the tissues and prevent further tissue damage<sup>[5]</sup>.

The FDA has approved several biologics for clinical use in certain rheumatological conditions. Other drugs, while not FDA approved, have been given orphan status for use in rheumatological conditions<sup>[12]</sup>. This is not the case for uveitis. Until recently, there were very few controlled clinical studies of biologics in uveitis vying for FDA approval amongst which Adalimumab was FDA approved for use in non-infectious uveitis. In the last several years multiple studies using several biologics have been either completed or are in progress<sup>[13]</sup>.

In this review, we attempt to outline, summarize, and provide updates on the agents that have been evaluated in uveitis. These therapies are aimed to target an underlying mechanism of inflammation<sup>[6]</sup>. There are multiple targets for biologics in uveitis, with the most common being TNF- $\alpha$  inhibitors. At the present time, only TNF- $\alpha$  inhibitors are recommended for treatment of idiopathic uveitis that have failed conventional immunosuppressants<sup>[14]</sup>. In addition to TNF- $\alpha$  inhibitors, other biologics including specific interleukins and surface proteins are being evaluated. The algorithm for treatment of uveitis generally begins with initial systemic steroid treatment, and if the patient worsens or cannot maintain long term steroid administration, antimetabolites are recommended which can be replaced with alkylating agents based on effect desired. If this is unsuccessful, t-cell inhibitors or biologics can be used individually or added to the antimetabolites.

#### Classification of Biologics in Uveitis

Based on their mechanism of action, biologics used in Uveitis can broadly be classified into following categories:

1. TNF- $\alpha$  inhibitors
1. Anti-interleukin/Anti-lymphocyte
1. Specific Receptor antagonists
2. Interferons

#### TNF- $\alpha$ -Inhibitors:

Tumour Necrosis Factor, known as TNF- $\alpha$ , is a pro-inflammatory cytokine involved in a variety of inflammatory conditions including eye and it is the most commonly studied mediator of inflammation in uveitis<sup>[32]</sup>.

Proteolytic cleavage from the cell surface creates the soluble form<sup>[33]</sup>. Therefore, its blockade was hypothesized to be helpful in decreasing the inflammation in uveitis and to be useful in its management. Specifically, inhibition of TNF- $\alpha$  leads to decreased intraocular inflammation by decreased interleukin-4 (IL-4) and decreased interferon-gamma<sup>[34]</sup>. The TNF- $\alpha$  inhibitors studied are primarily adalimumab and infliximab.

#### Adalimumab:

While most targeted therapies using biologic agents are still second line in the management of uveitis, Adalimumab has also been effectively used as first line in Behçet's disease<sup>[35]</sup>. It is a fully humanised monoclonal antibody directed against soluble and membrane-bound TNF- $\alpha$ <sup>[36]</sup>. It has the advantage of being administered as a subcutaneous injection that patients can self-inject at home, rather than requiring hospital admission for intravenous infusions<sup>[37]</sup>. Anti-TNF- $\alpha$  therapy has been shown to prevent flares of anterior uveitis in a clinically relevant number of patients with severe Ankylosing Spondylitis<sup>[38]</sup>. In a phase 3 trial, adalimumab was found to be correlated with a lower risk of uveitic flare but it was found that the patients were more likely to experience adverse or serious adverse events compared to the group receiving a placebo (i.e. injection site reactions, allergic reactions, blurred vision, reduced visual acuity)<sup>[39]</sup>. This is the only biologic agent so far approved by FDA for use in non-infectious uveitis.

#### Infliximab:

Infliximab has been shown to be effective in uveitis but has not achieved FDA approval. Infliximab is a chimeric immunoglobulin-G1 monoclonal antibody that also targets TNF- $\alpha$  with high affinity<sup>[18]</sup>. In a review of 44 patients with refractory uveitis associated with Behçet's Disease, it was found that infliximab increased visual acuity in these patients and decreased the frequency of ocular attacks. However, it was found that over the 5-year treatment period, doses were needed more frequently to maintain therapy outcomes<sup>[40]</sup>. In a prospective study of 63 uveoretinitis patients, mean visual acuity had improved in 92% of patients<sup>[41]</sup>. In paediatric patients, a retrospective case review of six patients showed a decrease in ocular inflammation in all six patients<sup>[42]</sup>. A prospective study showed that vitritis, macular oedema, and vasculitis were resolved in 90% of patients with Behçet's disease related uveitis<sup>[43]</sup>. A retrospective, interventional 88 patient cohort study showed that of the 81.8% of patients achieved clinical remission of recalcitrant uveitis with infliximab treatment but 58.3% required additional immunomodulatory medications<sup>[44]</sup>.

**Etanercept:**

Etanercept is a receptor fusion protein, a genetically engineered fusion protein composed of a dimer of the extracellular portions of TNF receptor 2 fused to the Fc portion of human immunoglobulin G-1<sup>[45]</sup>. It is indicated that there has been more success with monoclonal anti-TNF agents rather than fusion proteins and etanercept has not been as successful as other TNF- $\alpha$  inhibitors<sup>[46]</sup>. There is also currently debate regarding onset of uveitis due to etanercept treatment for other diseases including spondyloarthropathies, psoriatic arthritis and inflammatory bowel disease<sup>[47]</sup>. A randomized control trial of 20 patients found that etanercept has no significant efficacy over placebo in preventing uveitic relapses<sup>[48]</sup>.

**Golimumab:**

Golimumab, like adalimumab, is a human monoclonal antibody that targets TNF. Golimumab has found to be clinically successful in the treatment of rheumatoid arthritis, psoriatic arthritis, and ankylosing spondylitis<sup>[49]</sup>. In a retrospective analysis of intraocular inflammation in Behcet's disease, golimumab was found to be efficacious in reducing intraocular inflammation with regards to reducing uveitic relapses and resolving active retinal vasculitis<sup>[24]</sup>. In a multicentre prospective study of ankylosing spondylitis patients with uveitis, the occurrence rate of uveitis and the disease activity was decreased significantly after treatment with golimumab<sup>[50]</sup>.

**Certolizumab:**

Certolizumab is a monovalent fragment antigen-binding antibody which is covalently linked to polyethylene glycol<sup>[51]</sup>; this is a humanized protein that was derived from a mouse anti-TNF monoclonal antibody. Certolizumab has been successful in treatment of rheumatoid arthritis<sup>[52]</sup> and has been found to be associated with lower incidences of uveitis<sup>[46]</sup>.

Molecular structure of TNF alpha antagonists : Adalimumab and golimumab are fully human IgG1 monoclonal anti-TNF antibodies. Infliximab is a mouse or human chimeric monoclonal anti-TNF antibody of IgG1 isotype. Etanercept is a fusion protein of TNFR2 (p75) and the Fc region of human IgG1. Certolizumab is a PEGylated Fab' fragment of a humanized IgG1 monoclonal anti-TNF antibody. Adapted from D. Tracey et al. / Pharmacology & Therapeutics 117 (2008) 244–279.

**Anti-interleukin/Anti-lymphocyte:**

In uveitis, cytokines are produced by monocytes, macrophages, and T-lymphocytes. These cytokines are involved in causing an inflammatory response with aqueous humour levels correlating with serum cytokine levels and disease severity<sup>[53]</sup>. Anti-interleukin/Anti-lymphocyte drugs act against these cytokines.

**Abatacept:**

Abatacept is a recombinant fusion protein that inhibits activation of T lymphocytes by blocking CD28 to CD80/CD86 cells. This protein joins the extracellular domain of CTLA-4 to the Fc fragment of human IgG1 and inhibits the activation of T-cells<sup>[49]</sup>. It is used in treatment of JIA for children over 6 years of age and can be used in patients with persistent uveitis even when being treated with other medications<sup>[54]</sup>. A multicentre study determined that abatacept improved JIA-related uveitis when used as a first-line or second-line treatment<sup>[55]</sup>.

**Rituximab:**

Rituximab is an anti-CD20 B cell chimeric monoclonal antibody therapy. It has been shown to be successful for treatment of rheumatoid arthritis and is especially used to treat autoimmune diseases that do not respond effectively to TNF- $\alpha$  blockers<sup>[56]</sup>. In a randomized control trial, rituximab with methotrexate was found to show improvement in total adjusted disease activity index but further research is needed due to increased relapse after B cell depletion no longer occurred, indicating a potentially longer treatment period<sup>[57]</sup>. Rituximab has also been observed to be beneficial in decreasing subretinal fibrosis uveitis syndrome with a decrease in macular involvement and visual loss<sup>[58]</sup>.

**Anakinra:**

Interleukin-1 is an inflammatory cytokine with two ligands (IL-1 $\alpha$  and IL-1 $\beta$ ) which will induce secondary inflammatory mediators such as additional cytokines, chemokines, and prostaglandins<sup>[8]</sup>. The two ligands are present in different cell types with IL-1 $\alpha$  being present in epithelial and endothelial cells and IL-1 $\beta$  being present in myeloid cells<sup>[59]</sup>.

Interleukin-1 is indicated in many types of inflammatory diseases including rheumatoid arthritis, atherosclerosis, and gout. Anakinra is a recombinant form of IL-1Ra, which is a natural IL-1 receptor antagonist. Anakinra will block the binding of both ligands and prevent the mediated inflammation<sup>[60]</sup>. Currently, anakinra is approved for rheumatoid arthritis and cryopyrin-associated periodic syndromes however it is not as potent of a treatment as anti-TNF $\alpha$ <sup>[61]</sup>. There has been individual success in treatment of uveitis with anakinra but a clinical trial is necessary to determine its efficacy<sup>[25]</sup>.

The IL-1 receptor antagonist anakinra competitively inhibits the binding of IL-1 to the IL-1 receptor. Abatacept, a CTLA4-Ig fusion protein, is an inhibitor of T-cell activation. The chimeric anti-CD20 monoclonal antibody rituximab acts to deplete B cells. Adapted from van Vollenhoven, R. F. Nat. Rev. Rheumatol. 7, 205–215 (2011).

### Specific Receptor Antagonists

#### Canakinumab:

Canakinumab is a human monoclonal antibody that binds to IL-1 $\beta$  and decreases the inflammatory process of many diseases including rheumatologic disease<sup>[62]</sup>. Canakinumab has been found to decrease low-grade systemic inflammation in atherosclerosis and reduces major cardiovascular events<sup>[63]</sup>. The major cytokine in juvenile idiopathic arthritis is IL-1 $\beta$  and therefore, canakinumab has been used in treatment of inflammation in this disease and has been found to have a rapid reduction in inflammation gene expression<sup>[64]</sup>. In patients with uveitis, canakinumab was found to suppress ocular attacks and decrease retinal vascular involvement<sup>[65]</sup>.

#### Gevokizumab

Gevokizumab is a humanized anti IL-1 $\beta$  antibody that has been studied in coronary dysfunction, inflammatory skin disease, and Behcet's disease<sup>[65]</sup>. In an exploratory study, gevokizumab was found to be well tolerated in patients with uveitis related to Behcet's disease and controlled acute ocular exacerbations without the need for corticosteroids<sup>[20]</sup>.

#### Tocilizumab:

Tocilizumab, also known as myeloma receptor antibody, is a recombinant IgG1 monoclonal antibody directed against soluble and membrane-bound IL-6 receptors. This binding of IL-6 receptors will inhibit IL-6 mediated immunological signalling and therefore induce expansion of B-regulatory cells and decrease expression of cytokine and chemokine genes. Tocilizumab is FDA approved, specifically for the treatment of rheumatoid arthritis and polyarticular juvenile idiopathic arthritis<sup>[66]</sup>. The success of tocilizumab as a treatment for rheumatoid arthritis has been established in many randomized control trials<sup>[67]</sup> and investigation is ongoing into using tocilizumab as a treatment for thyroid eye disease<sup>[68]</sup>, giant-cell arteritis<sup>[69]</sup> and uveitis.

IL-6 is elevated in the intraocular fluid of patients currently experiencing uveitis. Due to this interaction, tocilizumab has been investigated as a treatment method for uveitis. In a large multicentre, randomized trial, TCZ was found to improve visual acuity and reduce vitreous haze and central macular thickness in eyes with non-infectious intermediate uveitis, posterior uveitis, and panuveitis in the time period of six months<sup>[70]</sup>. Tocilizumab has also been shown to have success in patients who did not have success with other treatment methods such as anti-TNF- $\alpha$  and adalimumab<sup>[71]</sup>.

#### Secukinumab:

Secukinumab, a human monoclonal antibody directed against Interleukin-17A (IL-17A). Secukinumab has been found to have success in the treatment of psoriasis and psoriatic arthritis<sup>[72]</sup>.

In Behcet's Disease, a high ratio of Th17/Th1 has been demonstrated with regards to uveitis and folliculitis and therefore, it was thought that a therapy targeting this ratio would be successful<sup>[57]</sup>. However, it has not shown to have demonstrative efficacy in a study that included three randomized controlled clinical trials in uveitis<sup>[57]</sup>.

#### Ustekinumab:

Ustekinumab is a monoclonal antibody to the p40 subunit of interleukin (IL)-12 and IL-23 cytokines. Ustekinumab has been found to be successful in alleviating inflammation in moderate to severe Crohn's disease<sup>[73]</sup>. Thus far, only one case of Behcet's disease uveitis has been reported as being treated with subcutaneous ustekinumab with success within three months<sup>[74]</sup>.

#### Alemtuzumab:

Alemtuzumab is a human monoclonal antibody against cell surface CD52 and is used in treatment of chronic lymphocytic leukaemia, multiple sclerosis and rheumatoid arthritis. CD52 is found in B and T lymphocytes, thymocytes, and monocytes although function is unknown<sup>[75]</sup>. There is currently indirect data on uveitis showing four patients, two of whom had complete remission after 6 months of alemtuzumab treatment and two that had partial improvement<sup>[27]</sup>. However, more research is needed to determine the efficacy of alemtuzumab for treatment of uveitis.

#### Interferon:

Interferon alpha (IFN- $\alpha$ ) has been shown to be efficacious for ocular manifestations and is often used as a second line treatment due to its cost and potential side effects. IFN was found to decrease the relapse rate and permit long-term remission even after treatment has ended<sup>[76]</sup>. Interferons are relatively new drugs and still need to have efficacy and safety investigated<sup>[77]</sup>.

#### Work-up prior to starting Biologics:

##### Clinical Evaluation:

Careful clinical examination by a physician is essential before starting therapy with biologicals to rule out congestive heart failure, demyelinating diseases, Infections and malignancies

##### Laboratory tests:

1. Complete blood counts before starting therapy and every 3 months while patient is on therapy
2. Liver and Renal Function test along with serum electrolytes before starting therapy and every 3 monthly while patient is on therapy
3. Mantoux Test, Quantiferon TB gold test and High Resolution CT scan of Chest to rule out Tuberculosis before starting therapy. Annual Mantoux Test/ Quantiferon TB gold test while patient is on therapy.
4. HbSAg and HCV titres before starting therapy to rule out active infectious Hepatitis

### Conclusion:

With the acquisition of better knowledge of the immune pathways in uveitis and with the development and testing of targeted biologics, there is great hope for patients with uveitis. Standardization of Uveitis Nomenclature (SUN) project and the standardization of diagnostic criteria in uveitis has helped immensely to advance both the management of uveitis clinically and in evaluating studies<sup>[78,79]</sup>. Adamulibab marketed as Humira is the only biologic that has so far been approved by the FDA for use in uveitis<sup>[6]</sup>. More clinical trials are needed to move biologicals from off-label to formal approved use in uveitis<sup>[6]</sup>. Some agents, while not approved by the FDA, have been approved to be used in other systemic illnesses or organ transplant cases and are known as Orphan Drugs<sup>[80]</sup>. There are currently three uveitis orphan drugs have been approved by the FDA: secukinumab for chronic non-infectious uveitis, gevokizumab for non-infectious intermediate, posterior or pan-uveitis or chronic non-infectious anterior uveitis, and anti-tumour necrosis factor alpha monoclonal antibody<sup>[12]</sup>.

However, caution must be exercised with the use of biologic agents as their use is not without side effects. These agents are likely to cause activation of systemic infections such as tuberculosis and hepatitis thus it is essential to exclude any infectious cause of uveitis or presence of systemic focus of infection before considering biologic agents as a treatment option. Availability as well as cost is another factor that limits the use of these agents. Uveitis with systemic manifestations such as JIA or Behcet's disease patients are most likely to benefit from the use of biologics. Biologics can be considered as treatment of choice in non-infectious uveitis when conventional immunosuppressive therapy has failed or has been poorly tolerated, or in acute vision-threatening non-infectious uveitis when corticosteroid therapy is contraindicated and the onset of immunomodulatory agents will be delayed.

The advent and expansion of knowledge of mediators, cell receptors, immune pathways, and the development of uniform nomenclature both in diagnosis and evaluation of treatment has unleashed many new and potentially available targeted treatment options in the armamentarium of ophthalmologists. Preliminary promising results have opened a new horizon in the management of immune Uveitis. Research in this direction will need to continue to understand a whole new world of targeted treatment options for the benefit of patients suffering from idiopathic immune uveitis.

### References

1. Bodaghi B, Cassoux N, Wechsler B, Hannouche D, Fardeau C, Papo T, et al. Chronic Severe Uveitis: Etiology and Visual Outcome in 927 Patients from a Single Center. 2001;80(4):263-70.
2. Suttorp-Schulten MS, Rothova A. The possible impact of uveitis in blindness: a literature survey. *British Journal of Ophthalmology*. 1996;80(9):844.
3. Barisani-Asenbauer T, Maca SM, Mejdoubi L, Emminger W, Machold K, Auer H. Uveitis- a rare disease often associated with systemic diseases and infections- a systematic review of 2619 patients. *Orphanet Journal of Rare Diseases*. 2012;7(1):57.
4. Krishna U, Ajanaku D, Denniston AK, Gkika T. Uveitis: a sight-threatening disease which can impact all systems. *Postgraduate Medical Journal*. 2017;93(1106):766.
5. Priyanka JB. Biologicals in uveitis. 2017;5(1):3-10.
6. Duica I, Voinea L-M, Mitulescu C, Istrate S, Coman I-C, Ciuluvica R. The use of biologic therapies in uveitis. *Romanian Journal of Ophthalmology*. 2018;62(2):105-13.
7. McNally TW, Damato EM, Murray PI, Denniston AK, Barry RJ. An update on the use of biologic therapies in the management of uveitis in Behçet's disease: a comprehensive review. *Orphanet Journal of Rare Diseases*. 2017;12(1):130.
8. Barry RJ, Nguyen QD, Lee RW, Murray PI, Denniston AK. Pharmacotherapy for uveitis: current management and emerging therapy. *Clin Ophthalmol*. 2014;8:1891-911.
9. Asproudis I, Katsanos A, Kozeis N, Tantou A, Konstas AG. Update on the Treatment of Uveitis in Patients with Juvenile Idiopathic Arthritis: A Review. *Advances in Therapy*. 2017;34(12):2558-65.
10. Rider P, Carmi Y, Cohen I. Biologics for Targeting Inflammatory Cytokines, Clinical Uses, and Limitations. *International journal of cell biology*. 2016;2016:9259646.
11. Shahab MA, Mir TA, Zafar S. Optimising drug therapy for non-infectious uveitis. *International ophthalmology*. 2018.
12. Lutz T, Lampert A, Hoffmann GF, Ries M. Novel treatments for rare rheumatologic disorders: analysis of the impact of 30 years of the US orphan drug act. *Orphanet J Rare Dis*. 2016;11(1):60.
13. You C, Sahawneh HF, Ma L, Kubaisi B, Schmidt A, Foster CS. A review and update on orphan drugs for the treatment of noninfectious uveitis. *Clin Ophthalmol*. 2017;11:257-65.
14. Seve P, Kodjikian L, Adelaide L, Jamilloux Y. Uveitis in adults: What do rheumatologists need to know? Joint, bone, spine : revue du rhumatisme. 2015;82(5):308-14. E
15. Sheppard J, Joshi A, Betts KA, Hudgens S, Tari S, Chen N, et al. Effect of Adalimumab on Visual Functioning in Patients With Noninfectious Intermediate Uveitis, Posterior Uveitis, and Panuveitis in the VISUAL-1 and VISUAL-2 Trials. *JAMA ophthalmology*. 2017;135(6):511-8. Epub 2017/04/20. doi: 10.1001/jamaophthalmol.2017.0603.

16. Scheinfeld N. Adalimumab: a review of side effects. *Expert Opinion on Drug Safety*. 2005;4(4):637-41.
17. Guzelant G, Ucar D, Esatoglu SN, Hatemi G, Ozyazgan Y, Yurdakul S, et al. Infliximab for uveitis of Behçet's syndrome: a trend for earlier initiation. *Clinical and experimental rheumatology*. 2017;35 Suppl 108(6):86-9.
18. Takeuchi M, Kezuka T, Sugita S, Keino H, Namba K, Kaburaki T, et al. Evaluation of the long-term efficacy and safety of infliximab treatment for uveitis in Behçet's disease: a multicenter study. *Ophthalmology*. 2014;121(10):1877-84.
19. Tynjälä P, Lindahl P, Honkanen V, Lahdenne P, Kotaniemi K. Infliximab and etanercept in the treatment of chronic uveitis associated with refractory juvenile idiopathic arthritis. *Annals of the rheumatic diseases*. 2007;66(4):548-50.
20. Tugal-Tutkun I, Kadayifcilar S, Khairallah M, Lee SC, Ozdal P, Özyazgan Y, et al. Safety and Efficacy of Gevokizumab in Patients with Behçet's Disease Uveitis: Results of an Exploratory Phase 2 Study. *Ocular Immunology and Inflammation*. 2017;25(1):62-70.
21. Sanchez-Cano D, Callejas-Rubio JL, Ruiz-Villaverde R, Rios-Fernandez R, Ortego-Centeno N. Off-label uses of anti-TNF therapy in three frequent disorders: Behçet's disease, sarcoidosis, and noninfectious uveitis. *Mediators of inflammation*. 2013;2013:286857.
22. Letko E, Yeh S, Foster CS, Pleyer U, Brigell M, Grosskreutz CL. Efficacy and Safety of Intravenous Secukinumab in Noninfectious Uveitis Requiring Steroid-Sparing Immunosuppressive Therapy. *Ophthalmology*. 2015;122(5):939-48. doi:
23. Sen ES, Ramanan AV. Juvenile idiopathic arthritis-associated uveitis. *Best practice & research Clinical rheumatology*. 2017;31(4):517-34..
24. Fabiani C, Vitale A, Emmi G, Vannozzi L, Lopalco G, Guerriero S, et al. Efficacy and safety of adalimumab in Behçet's disease-related uveitis: a multicenter retrospective observational study. *Clinical rheumatology*. 2017;36(1):183-9.
25. Orlando I, Vitale A, Rigante D, Lopalco G, Fabiani C, Cantarini L. Long-term efficacy and safety of the interleukin-1 inhibitors anakinra and canakinumab in refractory Behçet disease uveitis and concomitant bladder papillary carcinoma. *Internal medicine journal*. 2017;47(9):1086-8.
26. Tugal-Tutkun I, Pavesio C, De Cordoue A, Bernard-Poenaru O, Gül A. Use of Gevokizumab in Patients with Behçet's Disease Uveitis: An International, Randomized, Double-Masked, Placebo-Controlled Study and Open-Label Extension Study. *Ocular Immunology and Inflammation*. 2018;26(7):1023-33.
27. Pasadhika S, Rosenbaum JT. Update on the use of systemic biologic agents in the treatment of noninfectious uveitis. *Biologics : targets & therapy*. 2014;8:67-81.
28. Mugheddu C, Atzori L, Del Piano M, Lappi A, Pau M, Murgia S, et al. Successful ustekinumab treatment of noninfectious uveitis and concomitant severe psoriatic arthritis and plaque psoriasis. *Dermatologic therapy*. 2017;30(5).
29. Alokaily F, Al Saati A, Jawad A. Successful treatment of Behçet's uveitis with Tocilizumab. *Saudi journal of ophthalmology : official journal of the Saudi Ophthalmological Society*. 2017;31(1):42-4.
30. Jain N, Bhatti MT. Fingolimod-associated macular edema: incidence, detection, and management. *Neurology*. 2012;78(9):672-80
31. Hasanreisoglu M, Cubuk MO, Ozdek S, Gurelik G, Aktas Z, Hasanreisoglu B. Interferon Alpha-2a Therapy in Patients with Refractory Behçet Uveitis. *Ocul Immunol Inflamm*. 2017;25(1):71-5.
32. Deitch I, Amer R, Tomkins-Netzer O, Habot-Wilner Z, Friling R, Neumann R, et al. The effect of anti-tumor necrosis factor alpha agents on the outcome in pediatric uveitis of diverse etiologies. *Graefes's Archive for Clinical and Experimental Ophthalmology*. 2018;256(4):801-8.
33. Neri P, Arapi I, Nicolai M, Pirani V, Saitta A, Luchetti MM, et al. Biologic Therapy in Inflammatory Eye Conditions (Ophtalmology): Safety Profile. *Current drug safety*. 2016;11(1):47-54.
34. Cordero-Coma M, Sobrin L. Anti-tumor necrosis factor- $\alpha$  therapy in uveitis. *Survey of Ophthalmology*. 2015;60(6):575-89.
35. Vitale A, Emmi G, Lopalco G, Gentileschi S, Silvestri E, Fabiani C, et al. Adalimumab effectiveness in Behçet's disease: short and long-term data from a multicenter retrospective observational study. *Clinical rheumatology*. 2017;36(2):451-5.
36. Horiuchi T, Mitoma H, Harashima S, Tsukamoto H, Shimoda T. Transmembrane TNF-alpha: structure, function and interaction with anti-TNF agents. *Rheumatology (Oxford, England)*. 2010;49(7):1215-28.
37. Martín-Varillas JL, Calvo-Río V, Beltrán E, Sánchez-Bursón J, Mesquida M, Adán A, et al. Successful Optimization of Adalimumab Therapy in Refractory Uveitis Due to Behçet's Disease. *Ophthalmology*. 2018.
38. Braun J, Baraliakos X, Listing J, Sieper J. Decreased incidence of anterior uveitis in patients with ankylosing spondylitis treated with the anti-tumor necrosis factor agents infliximab and etanercept. *Arthritis and rheumatism*. 2005;52(8):2447-51. Epub 2005/07/30.
39. Jaffe GJ, Dick AD, Brézín AP, Nguyen QD, Thorne JE, Kestelyn P, et al. Adalimumab in Patients with Active Noninfectious Uveitis. *New England Journal of Medicine*. 2016;375(10):932-43.

40. Ueda S, Akahoshi M, Takeda A, Inoue Y, Omoto A, Ayano M, et al. Long-term efficacy of infliximab treatment and the predictors of treatment outcomes in patients with refractory uveitis associated with Behcet's disease. *European journal of rheumatology*. 2018;5(1):9-15.
41. Okada AA, Goto H, Ohno S, Mochizuki M. Multicenter study of infliximab for refractory uveoretinitis in Behcet disease. *Archives of ophthalmology (Chicago, Ill : 1960)*. 2012;130(5):592-8.
42. Rajaraman RT, Kimura Y, Li S, Haines K, Chu DS. Retrospective case review of pediatric patients with uveitis treated with infliximab. *Ophthalmology*. 2006;113(2):308-14.
43. Sfrikakis PP, Theodossiadis PG, Katsiari CG, Kaklamanis P, Markomichelakis NN. Effect of infliximab on sight-threatening panuveitis in Behcet's disease. *Lancet (London, England)*. 2001;358(9278):295-6.
44. Kruh JN, Yang P, Suelves AM, Foster CS. Infliximab for the treatment of refractory noninfectious Uveitis: a study of 88 patients with long-term follow-up. *Ophthalmology*. 2014;121(1):358-64.
45. Scott L. Etanercept: A Review of Its Use in Autoimmune Inflammatory Diseases. *Drugs*. 2014;74(12):1379-410.
46. Sharma SM, Jackson D. Uveitis and spondyloarthropathies. *Best practice & research Clinical rheumatology*. 2017;31(6):846-62. Epub 2018/12/05. doi: 10.1016/j.berh.2018.08.002.
47. Brito-Zeron P, Perez-Alvarez R, Ramos-Casals M. Etanercept and uveitis: friends or foes? *Current medical research and opinion*. 2015;31(2):251-2.
48. Foster CS, Tufail F, Waheed NK, Chu D, Miserocchi E, Baltatzis S, et al. Efficacy of etanercept in preventing relapse of uveitis controlled by methotrexate. *Archives of ophthalmology (Chicago, Ill : 1960)*. 2003;121(4):437-40.
49. Tahir Z, Kavanaugh A. The role of golimumab in inflammatory arthritis. A review of the evidence. *Therapeutic Advances in Musculoskeletal Disease*. 2018;10(9):181-94.
50. Van Bentum RE, Heslinga SC, Nurmohamed MT, Gerards AH, Griep EN, Koehorst CBJM, et al. Reduced Occurrence Rate of Acute Anterior Uveitis in Ankylosing Spondylitis Treated with Golimumab — The GO-EASY Study. *The Journal of Rheumatology*. 2018;jrheum.180312.
51. Biggioggero M, Crotti C, Becciolini A, Miserocchi E, Favalli EG. The Management of Acute Anterior Uveitis Complicating Spondyloarthritis: Present and Future %J *BioMed Research International*. 2018;2018:11.
52. Connock M, Tubeuf S, Malottki K, Uthman A, Round J, Bayliss S, et al. Certolizumab pegol (CIMZIA(R)) for the treatment of rheumatoid arthritis. *Health technology assessment (Winchester, England)*. 2010;14(Suppl. 2):1-10.
53. Ooi KG, Galatowicz G, Calder VL, Lightman SL. Cytokines and chemokines in uveitis: is there a correlation with clinical phenotype? *Clinical medicine & research*. 2006;4(4):294-309.
54. Bou R, Adán A, Borrás F, Bravo B, Calvo I, De Inocencio J, et al. Clinical management algorithm of uveitis associated with juvenile idiopathic arthritis: interdisciplinary panel consensus. *Rheumatology international*. 2015;35(5):777-85.
55. Birolo C, Zannin ME, Arsenyeva S, Cimaz R, Miserocchi E, Dubko M, et al. Comparable Efficacy of Abatacept Used as First-line or Second-line Biological Agent for Severe Juvenile Idiopathic Arthritis-related Uveitis. *J Rheumatol*. 2016;43(11):2068-73.
56. Miserocchi E, Modorati G, Berchicci L, Pontikaki I, Meroni P, Gerloni V. Long-term treatment with rituximab in severe juvenile idiopathic arthritis-associated uveitis. *British Journal of Ophthalmology*. 2016;100(6):782.
57. Sota J, Rigante D, Lopalco G, Frediani B, Franceschini R, Galeazzi M, et al. Biological therapies for the treatment of Behcet's disease-related uveitis beyond TNF-alpha blockade: a narrative review. *Rheumatology international*. 2018;38(1):25-35.
58. Cornish KS, Kuffova L, Forrester JV. Treatment of diffuse subretinal fibrosis uveitis with rituximab. *The British journal of ophthalmology*. 2015;99(2):153-4.
59. Dinarello CA. Interleukin-1 in the pathogenesis and treatment of inflammatory diseases. *Blood*. 2011;117(14):3720-32. doi: 10.1182/blood-2010-07-273417.
60. Planck SR, Woods A, Clowers JS, Nicklin MJ, Rosenbaum JT, Rosenzweig HL. Impact of IL-1 signalling on experimental uveitis and arthritis. *Annals of the Rheumatic Diseases*. 2012;71(5):753.
61. Ramirez J, Canete JD. Anakinra for the treatment of rheumatoid arthritis: a safety evaluation. *Expert Opin Drug Saf*. 2018;17(7):727-32.
62. Ridker PM, Everett BM, Thuren T, MacFadyen JG, Chang WH, Ballantyne C, et al. Antiinflammatory Therapy with Canakinumab for Atherosclerotic Disease. *New England Journal of Medicine*. 2017;377(12):1119-31.
63. Koenig W. Inflammation Revisited: Atherosclerosis in The Post-CANTOS Era. *European cardiology*. 2017;12(2):89-91.
64. Toplak N, Blazina S, Avcin T. The role of IL-1 inhibition in systemic juvenile idiopathic arthritis: current status and future perspectives. *Drug design, development and therapy*. 2018;12:1633-43.

65. Hatemi G, Seyahi E, Fresko I, Talarico R, Hamuryudan V. One year in review 2017: Behcet's syndrome. *Clinical and experimental rheumatology*. 2017;35 Suppl 108(6):3-15.
66. Yokota S, Imagawa T, Mori M, Miyamae T, Aihara Y, Takei S, et al. Efficacy and safety of tocilizumab in patients with systemic-onset juvenile idiopathic arthritis: a randomised, double-blind, placebo-controlled, withdrawal phase III trial. *Lancet* (London, England). 2008;371(9617):998-1006.
67. Scott LJ. Tocilizumab: A Review in Rheumatoid Arthritis. *Drugs*. 2017;77(17):1865-79.
68. Hamed Azzam S, Kang S, Salvi M, Ezra DG. Tocilizumab for thyroid eye disease. *The Cochrane database of systematic reviews*. 2018;11: Cd012984..
69. Stone JH, Tuckwell K, Dimonaco S, Klearman M, Aringer M, Blockmans D, et al. Trial of Tocilizumab in Giant-Cell Arteritis. *The New England journal of medicine*. 2017;377(4):317-28.
70. Sepah YJ, Sadiq MA, Chu DS, Dacey M, Gallemore R, Dayani P, et al. Primary (Month-6) Outcomes of the STOP-Uveitis Study: Evaluating the Safety, Tolerability, and Efficacy of Tocilizumab in Patients With Noninfectious Uveitis. *Am J Ophthalmol*. 2017;183:71-80.
71. Papo M, Bielefeld P, Vallet H, Seve P, Wechsler B, Cacoub P, et al. Tocilizumab in severe and refractory non-infectious uveitis. *Clinical and experimental rheumatology*. 2014;32(4 Suppl 84):S75-9.
72. Abrouk M, Gandy J, Nakamura M, Lee K, Brodsky M, Singh R, et al. Secukinumab in the Treatment of Psoriasis and Psoriatic Arthritis: A Review of the Literature. *Skin therapy letter*. 2017;22(4):1-6.
73. Lamb YN, Duggan ST. Ustekinumab: A Review in Moderate to Severe Crohn's Disease. *Drugs*. 2017;77(10):1105-14.
74. Caso F, Costa L, Rigante D, Lucherini OM, Caso P, Bascherini V, et al. Biological Treatments in Behcet's Disease: Beyond Anti-TNF Therapy; *J Mediators of Inflammation*. 2014;2014:14.
75. Riera R, Porfirio GJ, Torloni MR. Alemtuzumab for multiple sclerosis. *The Cochrane database of systematic reviews*. 2016;4: Cd011203. Epub 2016/04/16.
76. Diwo E, Gueudry J, Saadoun D, Weschler B, LeHoang P, Bodaghi B. Long-term Efficacy of Interferon in Severe Uveitis Associated with Behçet Disease. *Ocular Immunology and Inflammation*. 2017;25(1):76-84.
77. Celiker H, Kazokoglu H, Direskeneli H. Conventional immunosuppressive therapy in severe Behcet's Uveitis: the switch rate to the biological agents. *BMC Ophthalmology*. 2018;18(1).
78. de Smet MD, Taylor SRJ, Bodaghi B, Miserocchi E, Murray PI, Pleyer U, et al. Understanding uveitis: The impact of research on visual outcomes. *Progress in Retinal and Eye Research*. 2011;30(6):452-70.
79. Jabs DA, Nussenblatt RB, Rosenbaum JT. Standardization of uveitis nomenclature for reporting clinical data. Results of the First International Workshop. *Am J Ophthalmol*. 2005;140(3):509-16.
80. Heiligenhaus A, Minden K, Foll D, Pleyer U. Uveitis in juvenile idiopathic arthritis. *Deutsches Arzteblatt international*. 2015;112(6):92-100, i.

How to cite this article: Prabakaran S, Allen R, Shah A, Biswas J. Biologics: A New Paradigm in the Management of Noninfectious Uveitis. *Sci J Med & Vis Res Foun* 2019; 37: 12-19

## A Case of Sympathetic Ophthalmitis following Globe Rupture

Preeti Sharma,<sup>1</sup> Soumyadeep Hazra<sup>2</sup>

1. Associate consultant.  
Department of Uvea, Aditya  
Birla Sankara Nethralaya,  
Kolkata, West Bengal, India

2. Fellow, Department of Uvea,  
Aditya Birla Sankara  
Nethralaya, Kolkata, West  
Bengal, India

Author for Correspondence:

**Preeti Sharma**

Associate consultant.  
Department of Uvea, Aditya  
Birla Sankara Nethralaya,  
Kolkata, West Bengal, India

drpreetisharma@hotmail.com

### Abstract:

Sympathetic Ophthalmia (SO) is a rare bilateral granulomatous inflammation that occurs secondary to accidental or surgical insult to the uvea of one eye (exciting eye). Here, we report a case of SO in a young male patient with a history of globe rupture repair in the left eye who later on developed bilateral granulomatous inflammation with extensive symmetrical posterior segment involvement suggestive of right sympathetic ophthalmia; left eye being the exciting eye. Timely diagnosis and prompt intervention led to significant improvement in the final visual outcome.

**Keywords:** Combined Hamartoma of Retina and Retinal Pigment Epithelium, CHRRPE, Hamartoma, MultiColor imaging

### Introduction:

Sympathetic Ophthalmia (SO) is a bilateral diffuse granulomatous intraocular inflammation that occurs either after surgery or penetrating trauma to one eye in most of the cases. The injured eye is called the exciting eye while the fellow eye, developing inflammation, as the sympathizing eye.

The time from ocular injury to onset of SO ranges from a few days to decades, with 80% of the cases occurring within 3 months of injury and 90% within 1 year.<sup>1</sup> The sympathetic pathways are thought to be possibly involved from the inciting eye to the sympathizing eye.<sup>2</sup> There appears to be a cell-mediated immune response directed against ocular self-antigens found on photoreceptors, the retinal pigment epithelium (RPE) and/or choroidal melanocytes.

First recognized by Hippocrates, epidemiological estimates have shown the incidence to be 0.2% to 0.5% after penetrating ocular injuries and 0.01% after intraocular surgery. SO accounted for approximately 0.3% of the uveitis.<sup>3</sup>

SO occurs more often after non-surgical trauma.<sup>4</sup> SO has been reported after various intraocular procedures such as, cataract extraction, iridectomy, pars plana vitrectomy, and retinal detachment repair.<sup>5</sup> Patients with SO are more likely to express HLA-DR4, and closely related HLADQw3 and HLA-DRw53 phenotype.<sup>6</sup>

It is postulated that the injury to the exciting eye resulted in an absorption and dissemination of uveal pigment, which produced the hypersensitivity reaction in the injured eye.

Current evidence suggests that choroidal melanocytes alone as an inciting target is considered insufficient to induce SO. The cell-mediated immunity observed in SO could be directed against some uveal antigen, a retinal antigen or a surface antigen shared by photoreceptors, RPE, and choroidal melanocytes.<sup>7</sup>

### Case Report:

A 20 year old male patient presented with complaints of diminution of vision in right eye (OD) for the past 7-10 days which was gradually progressive in nature associated with pain and redness.

He gave a history of perforating injury to left eye (OS) 2 months back, following which he consulted elsewhere where he was diagnosed with superior sclero-corneal tear with iris prolapse along with hypopyon in left eye. He underwent globe rupture repair and was prescribed with oral steroid, which the patient had stopped 1 week back by himself. Patient had minimal improvement of vision post-surgery which reduced again after 1 month.

On examination, right eye best corrected Visual acuity (BCVA) was perception of light present (PL+) and projection of rays (PR) accurate whereas left eye BCVA was hand movement (HM). On Slit Lamp Examination OD showed conjunctival congestion, few Keratic Precipitates (KPs), anterior chamber (AC) fibrin, dilated sluggishly reactive pupil and iris pigments on lens and cells in the anterior vitreous face. OS had 2 sutures in-situ superiorly subsequent to repair for sclera-corneal tear along with posterior synechiae at that region along with non reactive dilated pupil, vitreous cells, organised hypopyon with peripheral anterior synechiae (PAS)

Applanation tonometry showed IOP of 8 mm Hg for both eyes (OU). Fundus examination showed bilateral disc edema with bilateral exudative bullous retinal detachment. Ultrasound of both eyes confirmed exudative retinal detachment with shifting fluid and minimal diffuse choroidal thickening. (Fig 1A, 1B). On fundus fluorescein angiography (FFA), both eyes were hazy with disc leak. (Fig 1C, 1D).



Clinical history and investigations supported the diagnosis of sympathetic ophthalmia. He was started on topical steroids and was advised for 1 gm intravenous methylprednisolone for 3 consecutive days followed by a course of systemic steroids (1mg/kg/day) in a tapering fashion. Azathioprine 50 mg thrice a day for 1 month with monthly taper was added too.

On review after 3 weeks BCVA was 1/60 and Counting finger -1 meter in OD and OS respectively. On slit Lamp Examination OD was quiet and OS had +3 AC reaction.

Fundus examination (OU) showed resolved disc edema, resolved retinal detachment, and mottled Retinal Pigment Epithelium (RPE) with scarring at macula (Fig 2 A & B). Optical Coherence Tomography (OCT) of the right eye showed dry fovea (Fig 2 C), while OCT of the left eye showed persistent subretinal fluid pockets (Fig 2 D). There was gross disorganisation of inner retinal layers and RPE atrophy in both eyes (Fig 2 C & D). Patient was advised to continue oral steroids as prescribed and guarded visual prognosis was explained to the patient. At 1 month of follow up BCVA in OD and OS improved to 6/45, N24 and 6/60, N24 respectively. Slit Lamp Examination showed quiet eyes with old cells in anterior vitreous face. Fundus examination showed mottled retinal pigment epithelium with macular scarring in both the eyes.

#### Discussion:

SO presents as a bilateral pan uveitis. Patients report insidious onset of blurry vision, pain, epiphora, and photophobia in the sympathizing, non-injured eye accompanied by conjunctival injection and a granulomatous AC reaction with mutton-fat KPs on the corneal endothelium with mild AC reaction. Our patient presented 60

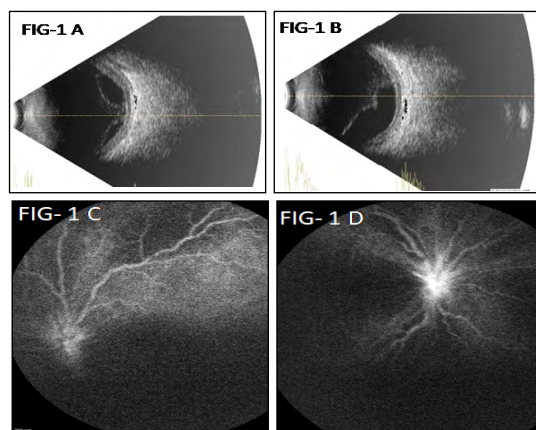


Fig. 1A & 1B - Ultrasonography B-scan report shows bullous exudative retinal detachment with choroidal thickening in right eye (OD) and left eye (OS) respectively.

Fig 1C & 1D - Fundus Fluorescein Angiography of both eyes showing disc leak. Rest of the details are unclear due to hazy view

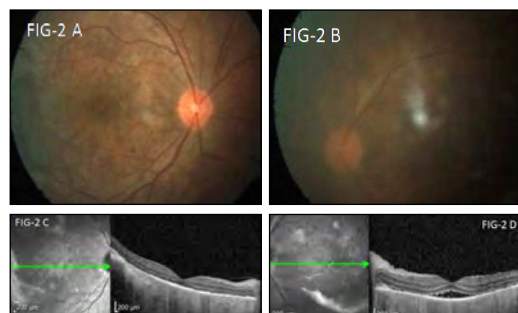

Fig 2A & Fig 2B: Fundus photo (OU) showed resolved disc edema, resolved retinal detachment and mottled Retinal Pigment Epithelium (RPE) with scarring at macula

Fig 2C: Right eye OCT macular scan shows dry fovea along with inner retinal layer disorganisation with RPE atrophy.

Fig 2D: Left eye OCT macular scan shows persistent subretinal fluid along with gross disorganisation of inner retinal layers

days after corneal tear repair in exciting eye and showed all the signs of anterior segment granulomatous inflammation in both eyes. Patients may have vitritis, retinal vasculitis, choroiditis, and papillitis. The extent of inflammation may sometimes be represented by serous retinal detachment and optic nerve swelling in affected patients.<sup>8</sup> White-yellowish lesions at the choroid are more common in the peripheral fundus of patients with SO (Dalen–Fuchs nodules).

Secondary glaucoma or cataract can be present. Retinal and optic atrophy may occur in association with retinal detachment, subretinal fibrosis, and underlying choroidal atrophy.<sup>9</sup> Choroidal neovascularization and phthisis bulbi are rare.

History and clinical examination are the mainstay of diagnosis of SO. However some imaging modalities like FFA, USG B Scan and OCT can be used as adjunct to support the diagnosis.

In the acute phase of SO, FFA typically demonstrates multiple hyperfluorescent leakage sites at the RPA during the venous phase that persist into the late frames of the study. In severe cases, pools of the exudates coalesce into large areas of exudative retinal detachment. Blocked choroidal fluorescence may occur when an intact dome of RPE contains the cellular elements of the Dalen–Fuchs nodules. Gradual accumulation of fluorescein into Dalen–Fuchs nodules may produce focal hyperfluorescence. However, degeneration of the RPE overlying the Dalen–Fuchs nodule may allow fluorescein dye to permeate focally into the RPE and gradually accumulate in the subretinal space.<sup>10</sup>

OCT shows subretinal fluids in cases of exudative retinal separation and it is a good tool to assess clinical outcome. Indocyanine Green (ICG) -V studies show multifocal hypofluorescent spots that became more prominent as the study progresses.<sup>11</sup>

B-scan Ultrasonography in SO demonstrates marked choroidal thickening and retinal detachment as seen in our patient.

The mainstay of treatment is systemic immunomodulatory therapy. Systemic corticosteroids are the first-line therapy for SO. Treatment is initiated with high dosage oral prednisolone (1.0 to 2.0 mg/kg/day) and tapered slowly over 3 to 4 months. In severe cases, intravenous pulse steroid therapy can be employed (Methylprednisolone 1.0g/day for 3 days). Adjunctive topical corticosteroids and cycloplegics are used to control anterior segment inflammation.

Immunomodulators are indicated if the patient is steroid-resistant or is having intolerable side effects of steroid therapy. However in more severe cases and extensive posterior segment involvement immunomodulators can be combined with systemic steroid as first line treatment as we did in our patient. Most commonly used Immunomodulators in SO are cyclosporine and azathioprine. Immunomodulators are to be initiated only after ruling out infection.

Our patient responded well to combined therapy and had good visual outcome considering extensive bilateral anterior and posterior segment involvement.

Recently, it is proposed that fluocinolone acetonide implant provides inflammatory control and reduces the dependence on systemic immunosuppression in patients with SO.<sup>12</sup>

### Conclusion

Sympathetic ophthalmia is an ocular emergency which needs prompt management to achieve a favourable visual outcome. With current medical management including immunosuppressives and immunomodulators visual prognosis is relatively good. SO patients who had been on systemic corticosteroids need strict follow ups and systemic evaluations so that early identification and appropriate treatment of long term complications is possible.

### References:

1. Lubin JR, Albert DM, Weinstein M. Sixty-five years of sympathetic ophthalmia: A clinicopathologic review of 105 cases (1913-1978) *Ophthalmology*. 1980;87:109–21.
2. Mackenzie W. A practical treatise on the diseases of the eye. 3rd ed. Longmans: London; 1840. pp. 523–34.
3. Kilmartin DJ, Dick AD, Forrester JV. Prospective surveillance of sympathetic ophthalmia in the UK and Republic of Ireland. *Br J Ophthalmol*. 2000;84:259–63.
4. Liddy N, Stuart J. Sympathetic ophthalmia in Canada. *Can J Ophthalmol*. 1972;7:157–9.
5. Fankhauser F, Kwasniewska S, Van der Zypen E. Cyclodestructive procedures, I: Clinical and morphological aspects: A review. *Ophthalmologica*. 2004;218:77–95.
6. Davis JL, Mittal KK, Freidlin V, Mellow SR, Optican DC, Palestine AG, et al. HLA associations and ancestry in Vogt-Koyanagi-Harada disease and sympathetic ophthalmia. *Ophthalmology*. 1990;97:1137–42.
7. Jakobiec FA, Marboe CC, Knowles DM, Iwamoto T, Harrison W, Chang S, et al. Human sympathetic ophthalmia: An analysis of the inflammatory infiltrate by hybridoma-monoclonal antibodies, immunochemistry, and correlative electron microscopy. *Ophthalmology*. 1983;90:76–95.
8. Damico FM, Kiss S, Young LH. Sympathetic ophthalmia. *Semin Ophthalmol*. 2005;20:191–7.
9. Lim WK, Chee SP, Sng I, Nussenblatt RB, Chan CC. Immunopathology of progressive subretinal fibrosis: Variant of sympathetic ophthalmia. *Am J Ophthalmol*. 2004;138:475–7.
10. Reynard M, Riffenburgh R, Minckler D. Morphological variation of Dalen-Fuch nodules in Sympathetic ophthalmia. *Br J Ophthalmol*. 1985;69:197–201.
11. Bernasconi O, Auer C, Zografos L, Herbort CP. Indocyanine green angiographic findings in sympathetic ophthalmia. *Graefes Arch Clin Exp Ophthalmol*. 1998;236:635–8.
12. Mahajan VB, Gehrs KM, Goldstein DA, Fischer DH, Lopez JS, Folk JC. Management of sympathetic ophthalmia with the fluocinolone acetonide implant. *Ophthalmology*. 2009;116:552–7.

How to cite this article: Sharma P, Hazra S. A case of sympathetic ophthalmitis following globe rupture. *Sci J Med & Vis Res Foun* 2019; 37 : 20-22

# Role of Nested Polymerase Chain Reaction and Enzyme-Linked Immunosorbent Assay of Aqueous Aspirate in a Case of Atypical Toxoplasmic Panuveitis

Gazal Patnaik<sup>1</sup>, Janani M.K<sup>2</sup>, Jyotirmay Biswas<sup>3</sup>

1. Associate consultant,  
Department of Uvea, Aditya  
Birla Sankara Nethralaya,  
Kolkata, West Bengal, India

2. Senior scientist,  
Sankara Nethralaya Referral  
Laboratory, Chennai, India

3. Director, Department of  
Uvea and Ocular Pathology,  
Medical Research Foundation,  
Chennai, India.

Author for Correspondence:

**Gazal Patnaik**

Associate consultant,  
Department of Uvea, Aditya  
Birla Sankara Nethralaya,  
Kolkata, West Bengal, India  
drgpn@snmail.org

## Abstract:

Typical ophthalmoscopic features of the retinochoroidal lesions in toxoplasmosis forms the clinical diagnosis without any further need of investigations. This is the scenario in most cases but various atypical features may pose diagnostic challenge. We report a case of atypical toxoplasmic panuveitis with multifocal retinochoroiditis and dense diffuse vitritis in an immunocompetent individual forming a diagnostic dilemma and establish the role of nested polymerase chain reaction and Goldmann–Witmer coefficient from aqueous aspirate for confirming the clinical diagnosis.

**Keywords:** Atypical toxoplasmosis, Retinochoroidal lesions, Nested - PCR, Goldmann-Witmer coefficient, Enzyme-Linked Immunosorbent Assay

## Introduction:

Ocular Toxoplasmosis (OT) is one of the most common causes of posterior uveitis in both immunocompetent as well as immunocompromised patients. The clinical diagnosis of toxoplasmic retinochoroiditis is based upon ophthalmoscopic findings. The typical fundus abnormalities are unilateral focal necrotising retinochoroiditis. The active lesion is associated with an overlying localized vitritis, classically described as “headlight in the fog” appearance. Various atypical lesions described are large areas of retinal necrosis or retinochoroiditis without adjacent pigmented retinal scar or bilateral presentations, reported in immunosuppressed individuals.<sup>(1, 3)</sup> We report a case of atypical toxoplasmic panuveitis with multifocal retinochoroiditis and dense diffuse vitritis in an immunocompetent individual and the role of nested polymerase chain reaction with enzyme linked immune-sorbent assay of aqueous aspirate.

## Case Report –

A 68-year-old female presented to us with complains of painless diminution of vision in the right eye since 45 days. She has been locally diagnosed as ocular toxoplasmosis based on the raised serum IgG levels against toxoplasma and was started on systemic sulfadoxine-pyrimethamine and systemic corticosteroids. Following non-improvement, patient came to us for further management. Best-corrected visual acuity (BCVA) was 20/400 in the right eye and

6/6 in the left eye. Slit-lamp biomicroscopic examination revealed small keratic precipitates, aqueous cell 2+, aqueous flare 1+ and plenty of cells in anterior vitreous according to the Standardized Uveitis Nomenclature (SUN) classification (Figure 1).



Fig 1: Slit lamp photograph of the right eye showing fine keratic precipitates diffusely distributed over the corneal endothelium.

Fundus examination revealed few ill-defined yellowish-white lesions seen through the dense vitreous haze. Fundus examination of the left eye was unremarkable. The patient then underwent investigations to rule out other simulating uveitic condition which included negative Mantoux test, interferon gamma release assay, normal serum angiotensin converting enzyme and negative serologies for human immunodeficiency virus and syphilis. To establish the diagnosis, anterior chamber paracentesis of right eye was done under sterile precautions. Nested Polymerase Chain Reaction (PCR) from aqueous aspirate targeting B1 gene of *Toxoplasma gondii* genome was positive with 193 base pairs (Figure 2).

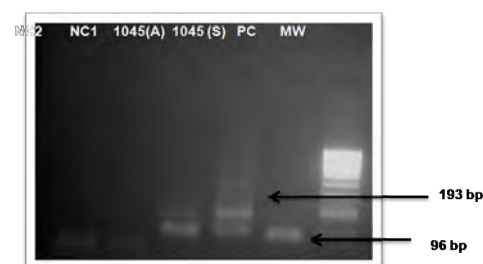


Fig 2: PCR showing positive reaction to toxoplasma B1 genome.

Goldmann-Witmer coefficient (GWC) was 1.174. She was then advised to start oral clindamycin, azithromycin and corticosteroids (60 mg/day). After 5 days, there was a marked reduction of vitreous inflammation. Multiple retinochoroidal lesions of varying sizes were now seen in parafoveal as well as peripheral retina in right eye (Figure 3). There was resolution of vitritis with healing of retinochoroidal lesions. However, vision remained stable at the end of 2 months of follow-up due to optic atrophy.

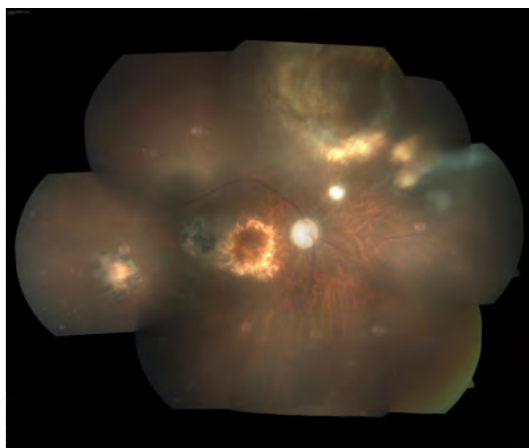


Fig 3: Fundus photograph of the right eye, following resolution of vitreous inflammation, showing multifocal retinochoroidal lesions with optic atrophy.

### Discussion

Toxoplasmosis is one of the commonest global zoonoses. In adults, the seroprevalence of antibodies against *Toxoplasma gondii* range from 22.5 - 80%. [1] Although the clinical manifestations of the disease are usually highly characteristic, described as 'headlight in the fog' appearance, atypical manifestations are not uncommon. Though diagnosis of OT is almost always clinical, atypical cases require laboratory investigations to clinch the diagnosis. Detection of toxoplasma-specific IgG levels in the serum is of low diagnostic value as once elevated remains so for the lifetime. Patients with OT always register serum positive for *Toxoplasma* specific IgG and so do infected individuals with no ocular involvement. Hence, OT diagnosis cannot rely upon lone detection of raised serum IgG levels [2] Samples of aqueous humor have been shown to register positive for *Toxoplasma* DNA more frequently in immunosuppressed.[3] However, our patient was immunocompetent. If the retinal lesions are typical for toxoplasmic retinochoroiditis, positive serum toxoplasma-specific IgG and negative IgM, responding to anti-toxoplasma therapy. In diagnostic dilemma, paired samples of aqueous humor and serum should be collected and analyzed in parallel. [4]If local IgG production is detected using the ELISA technique, then the clinical diagnosis can be considered confirmed. If no local specific IgG production is detected, or if the blood-retinal barrier is severely compromised, as was seen in our case with dense diffuse vitritis, a PCR analysis of the aqueous aspirate to detect DNA is recommended. A common method to estimate the local versus systemic toxoplasma-specific IgG is GWC index. A value of 2 or above is generally taken as evidence of the intraocular synthesis of *Toxoplasma* specific IgG. The sensitivity and the specificity of intraocular antibody detection have been reported to be 63 and 89%, respectively, although positivity rates up to 95% have

have been reported as well.[5,6]. However, GWC in our case was 1.174 which could be due to practical problem of inherently small volume of the samples that can be withdrawn, exacerbated by the low antibody levels that are usually present in aqueous [7] When the blood-retinal barrier is violated, the intraocular fluids are swamped with serum antibodies, high levels of which may mask the more subtle production in ocular compartments.[8]GWC being more than one but less than two in our case explains that a local reactivation is a possibility.Performing the three methods involving ocular samples(PCR, ELISA and GWC) together provided 89.4 % sensitivity and 98.9% specificity. [9]

Our case showed various atypical features including large multifocal retinochoroidal lesions in the periphery, dense diffuse vitritis along with anterior segment inflammation, not responding to the conventional anti-toxoplasmic medications that formed a diagnostic challenge .All the possible differentials were excluded with appropriate investigations. We performed all the three methods including serum and aqueous ELISA and aqueous PCR which improved both the sensitivity as well as specificity of the result giving a definitive diagnosis of ocular toxoplasmosis.

### Conclusion

To the best of our knowledge, very few reports has been made on role of PCR in toxoplasmic panuveitis with multifocal atypical retinochoroidal lesions and dense diffuse vitritis in an immunocompetent individual. [10]Our case posed a clinical challenge in the diagnosis of ocular toxoplasmosis which was resolved with aqueous PCR and antibody detection.

### References

1. Holland GN. Ocular toxoplasmosis: a global reassessment, Part I: epidemiology and course of disease. *Am J Ophthalmol* 2003;136:973–88.
2. Chapman DJ, Ashburn D, Ogston SA, Ho-Yen DO. The relationship between ocular toxoplasmosis and levels of specific toxoplasma antibodies. *Epidemiol Infect* 1999;122:299–303.
3. Fardeau C, Romand S, Rao NA, Cassoux N, Bettembourg O, Thulliez P et al. Diagnosis of toxoplasmic retinochoroiditis with atypical clinical features. *Am J Ophthalmol* 2002;134:196–203.
4. Villard O, Filisetti D, Roch-Deries F, Garweg J, Flament J, Candolfi E. Comparison of enzyme-linked immunosorbent assay, immunoblotting, and PCR for diagnosis of toxoplasmic chorioretinitis. *J Clin Microbiol* 2003;41:3537–41.

5. Fekkar A, Bodaghi B, Touafek F, Le Hoang P, Mazier D, Paris L. Comparison of immunoblotting, calculation of the Goldmann-Witmer coefficient, and real-time PCR using aqueous humor samples for diagnosis of ocular toxoplasmosis. *J Clin Microbiol* 2008;46:1965-7
6. De Groot-Mijnes JD, Rothova A, Van Loon AM, Schuller M, Ten Dam-Van Loon NH, De Boer JH et al. Polymerase chain reaction and Goldmann-Witmer coefficient analysis are complimentary for the diagnosis of infectious uveitis. *Am J Ophthalmol* 2006;141:313-18
7. Garweg JG. Determinants of immunodiagnostic success in human ocular toxoplasmosis. *Parasite Immunol* 2005;27:61-8
8. Kijlstra A, Luyendijk L, Baarsma GS, Rothova A, Schweitzer CM, Timmerman Z et al. Aqueous humor analysis as a diagnostic tool in toxoplasma uveitis. *Int Ophthalmol* 1989;13:383-6
9. Villard O, Filsetti D, Roch-Deries F, Garweg J, Flament J, Candolfi E. Comparison of Enzyme-Linked Immunosorbent Assay, Immunoblotting, and PCR for Diagnosis of Toxoplasmic Chorioretinitis. *J Clin Microbiol* 2003;41:3537-41.
10. Sudha K Ganesh, B Sowkath Ali, and H N Madhavan: Infectious chorioretinitis in an immunocompetent patient: A diagnostic dilemma. *Indian J Ophthalmol* 2017;65:1043-6.

How to cite this article: Patnaik G, Janani M K, Biswas J. Role of Nested Polymerase Chain Reaction and Enzyme-Linked Immunosorbent Assay of aqueous aspirate in a case of atypical toxoplasmic panuveitis. *Sci J Med & Vis Res Foun* 2019; 37 : 23-25

# Clinical and Imaging Features of Different Stages of Vogt-Koyanagi- Harada Syndrome

Preeti Sharma,<sup>1</sup> Soumyadeep Hazra<sup>2</sup>

1. Associate consultant.  
Department of Uvea, Aditya  
Birla Sankara Nethralaya,  
Kolkata, West Bengal, India

2. Fellow, Department of Uvea,  
Aditya Birla Sankara  
Nethralaya, Kolkata, West  
Bengal, India

Author for Correspondence:

**Preeti Sharma**

Associate consultant.  
Department of Uvea, Aditya  
Birla Sankara Nethralaya,  
Kolkata, West Bengal, India

drpreetisharma@hotmail.com

Clinical Features	Fundus Fluorescein Angiography (FFA)	Fundus Autofluorescence (FA)	Optical Coherence Tomography (OCT)	Ultrasound (B-SCAN, UBM)
<p><b>Stage 1: Prodromal</b></p> <p>Headache, Orbital pain, fever, Light sensitivity, Tearing, Optic neuritis.</p> <p>CSF pleocytosis.</p> <p><b>Neurologic and Auditory involvement.</b></p>	<p><b>A.Acute stage</b></p> <ul style="list-style-type: none"> <li>Numerous punctate hyperfluorescent dots at the level of RPE.(Fig 1A,1B)</li> </ul>	<p><b>A.Acute phase</b></p> <p>Mild uniform hyperautofluorescence in macula</p> <p>Areas of hypoautofluorescence in areas of serous retinal detachment.</p>	<p>Multifocal serous retinal detachment in acute VKH with cystic spaces and membranous structures continuous to the ellipsoid zone (internal and external segments junction of the photoreceptors.(FIG 3A,3B)</p>	<p><b>A.B-Scan</b></p> <p>Diffuse thickening of choroid, sclera and episclera.</p> <p>Vitreous opacities without posterior vitreous detachment</p> <p>Serous retinal detachment around posterior pole or inferiorly.(Fig 2A 2B)</p>
<p><b>Stage 2: Acute uveitic phase</b></p> <p>Bilateral: 70 %</p> <p><b>Anterior segment:</b> Corneal anaesthesia, Accomodative impairment, Tonic pupils, Mutton fat keratic precipitates, Iris nodules, Anterior chamber cells and flare and Acute angle closure glaucoma.</p> <p><b>Posterior segment:</b> Subretinal Fluid (SRF) accumulation- Optic nerve head (ONH) swelling- Exudative retinal detachment and maculopathy., Annular choroidal detachment, Vitritis,Dalen Fuch's Nodules-</p>	<p><b>B.Late stage</b></p> <ul style="list-style-type: none"> <li>Multiple serous retinal detachments with pooling of dye in subretinal space.</li> <li>Disc leakage. (Fig 1A, 1B)</li> </ul>	<p><b>B.Chronic phase</b></p> <p>Areas of hyper AF (peripapillary atrophy and retinal pigment epithelium loss)</p> <p>Hypo AF due to RPE proliferation.</p>		<p><b>B.UBM</b></p> <p>Swollen ciliary body, with ciliochoroidal detachment in 20 % cases.</p> <p>Shallow anterior chamber.</p>
<p><b>Stage 3: Convalescent phase</b></p> <p>"Sugaira's Sign "- Perilimbal vitiligo.</p> <p>"Sunset Glow Fundus" -depigmentation of choroid</p> <p>small atrophic lesions of choroid and RPE in the mid-periphery</p> <p>Vitiligo, Poliosis, Alopecia.</p> <p>Vitreomacular traction and Epiretinal membrane - due to RPE migration.</p>	<p><b>C.Convalescent stage</b></p> <ul style="list-style-type: none"> <li>Subretinal neovascular membrane.</li> <li>Retinochoroidal anastomosis.</li> <li>Vascular sheathing or staining.</li> </ul>			
<p><b>Stage 4: Chronic recurrent phase</b></p> <p>Recurrent Anterior and Posterior Uveitis or Panuveitis</p> <p>Ocular Hypotony.</p> <p>Pigment Epithelium depigmentation.</p> <p>Cataract , Glaucoma (angle closure or open angle)</p> <p>Neovascularisation of retina and disc,</p> <p>Subretinal fibrosis,</p> <p>Subretinal neovascular membrane,</p> <p>Arteriovenous anastomosis</p>	<p><b>D.Chronic and recurrent stages</b></p> <ul style="list-style-type: none"> <li>"Moth-eaten appearance"- due to alternating hyperfluorescence and hypofluorescence.</li> <li>Multiple hyperfluorescent RPE window defects (due to RPE atrophy) without progressive staining.</li> <li>Blocked fluorescence- due to RPE hyperplasia.</li> </ul>			

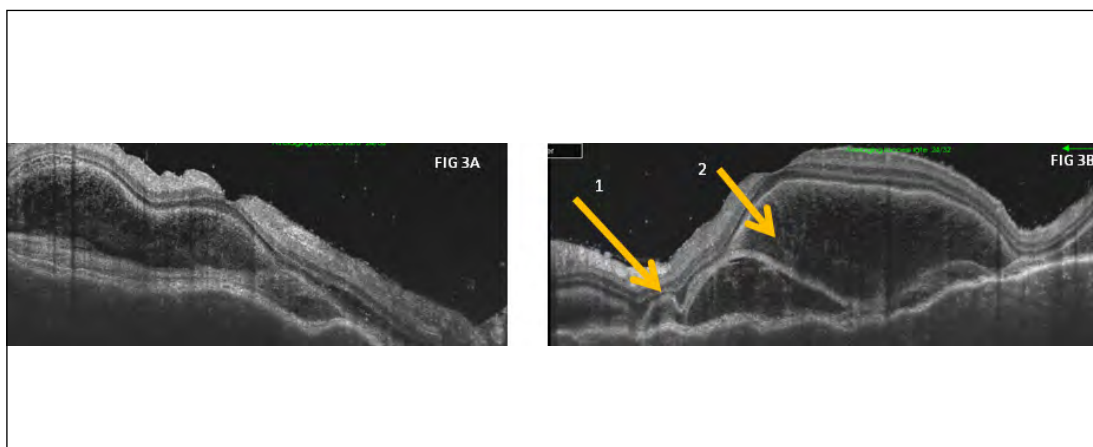
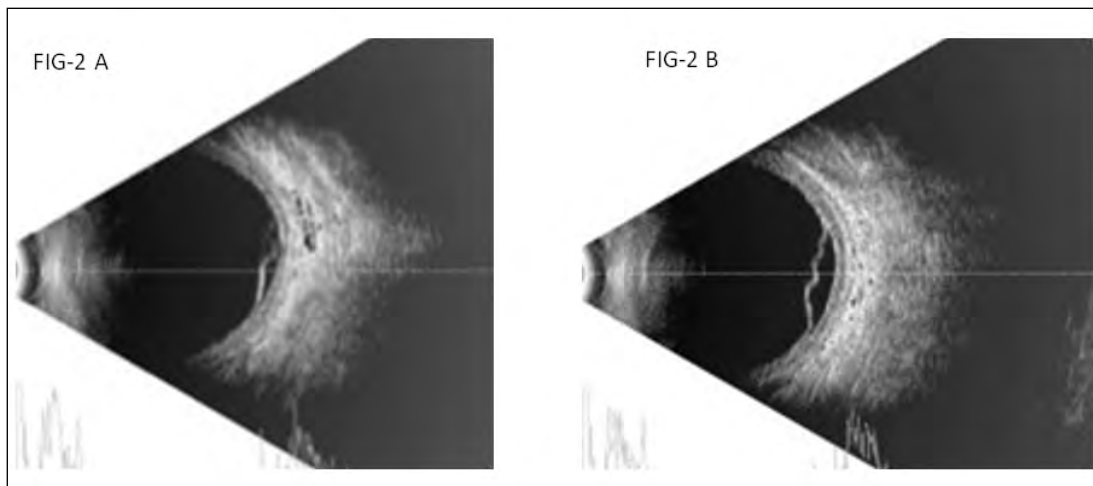
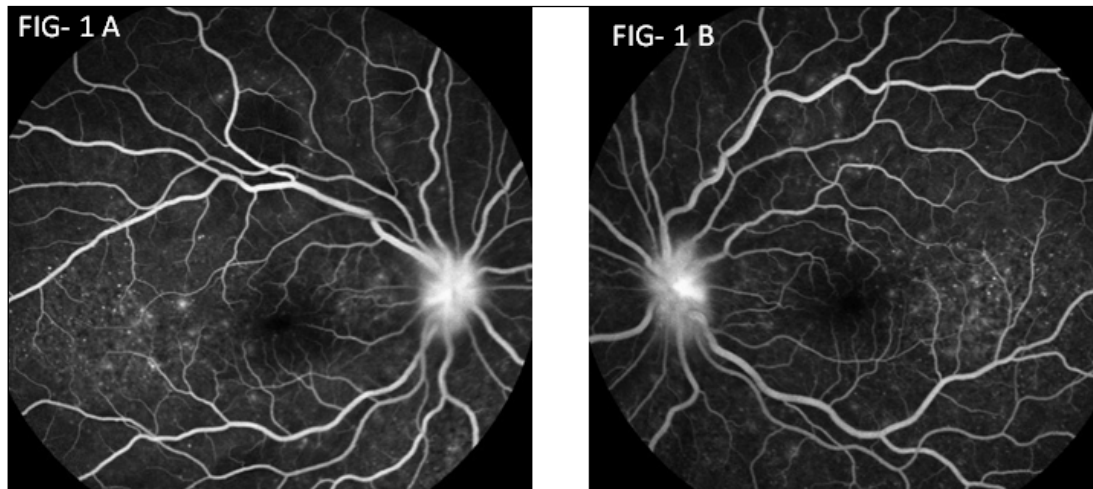


Fig 1A, 1B: Fundus Fluorescein Angiography (FFA) picture of Acute stage of VKH disease shows bilateral numerous punctate hyperfluorescent dots at the level of RPE associated with optic disc leakage.

Fig 2A, 2B: Ultrasound B-scan shows diffuse thickening of choroid with serous retinal detachment around posterior pole or inferiorly

Fig 3A, 3B : Swept source optical coherence tomography of OD (a) and OS (b) showing multilobular serous retinal detachment , subretinal septas (1), RPE undulations and hyper reflective dot reflexes in OU.

## Acute Retinal Necrosis

Amitabh Kumar<sup>1</sup>, Bhuvaneshwaran V<sup>2</sup>

1. Senior consultant.  
Department of Uvea, Aditya  
Birla Sankara Nethralaya,  
Kolkata, West Bengal, India

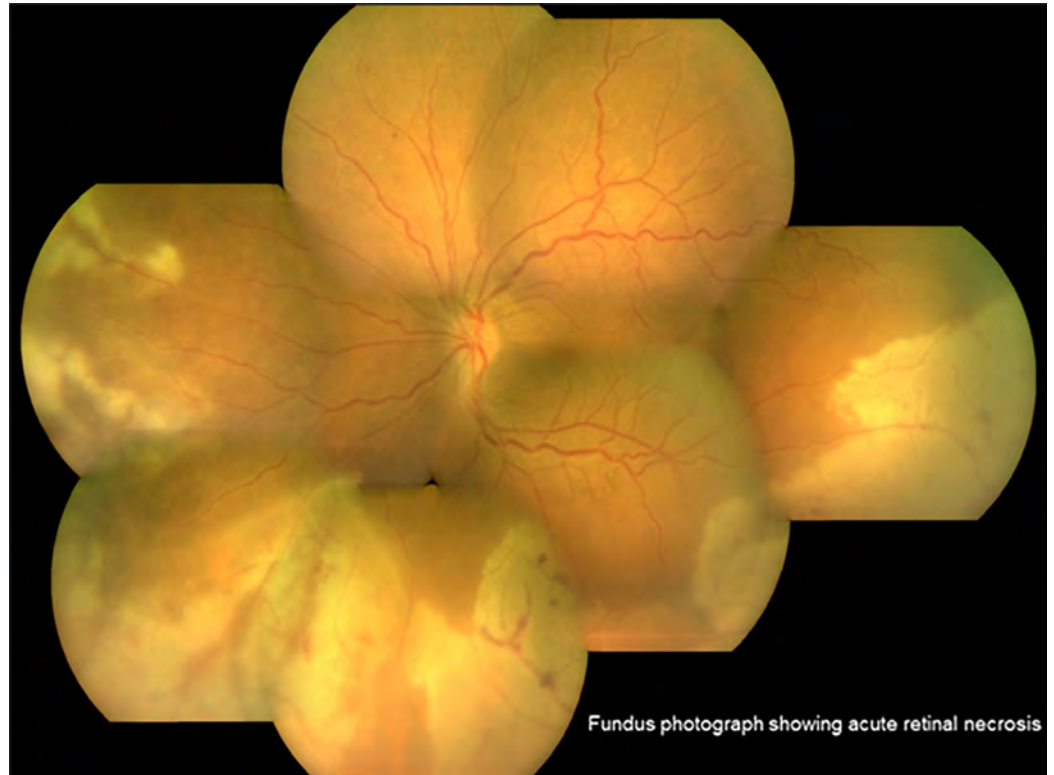
2. Fellow, Department of Uvea  
& Medical Retina, Aditya Birla  
Sankara Nethralaya, Kolkata,  
West Bengal, India

Author for Correspondence:

**Amitabh Kumar**

Senior consultant, Department  
of Uvea, Aditya Birla Sankara  
Nethralaya, Kolkata, West  
Bengal, India

drahk@snmail.org



Fundus photograph showing acute retinal necrosis

Acute retinal necrosis (ARN) is an ocular emergency and is caused by a viral infection. Most often the causative viral agent is either Varicella zoster virus (VZV) or Herpes simplex virus (HSV). Older patients present more often with VZV or HSV-1 infection while younger patients with HSV-2 infection. Although ARN is most commonly seen in healthy, immunocompetent individuals, immunosuppression may be a predisposing factor. Patients with ARN typically present with acute onset of vision loss in one or both the eyes, which may be associated with redness, photophobia, pain, floaters, and flashes. Classically, posterior segment involvement includes vitreous inflammation, retinal vascular arteriolitis, and peripheral retinitis. Retinitis typically begins as multifocal areas of retinal whitening and opacification with scalloped edges. Initially, this patchy retinitis usually appears peripherally and with progression becomes increasingly confluent and more posterior in its location. Retinal hemorrhages due to occlusive vasculitis may be seen. The diagnosis can be confirmed by polymerase chain reaction on an aqueous or vitreous sample for detection of a viral aetiology.

Treatment with antiviral therapy can be administered systemically (intravenously or orally) as well as locally with intravitreal injection. Steroids may be started under the cover of antivirals. Commonly used antiviral agents include acyclovir, valacyclovir, ganciclovir, valganciclovir which can be tapered slowly over months. Antiviral agents such as ganciclovir and foscarnet can be injected intravitreally as an adjunctive therapy. Patients with unilateral ARN should be closely followed with dilated examination of both the eyes. Common complications of ARN include retinal detachment and optic atrophy.

How to cite this article: Kumar A, Bhuvaneshwaran V. Acute retinal necrosis. Sci J Med & Vis Res Foun 2019; 37 : 28



## Vogt Koyanagi Harada Syndrome

Amitabh Kumar<sup>1</sup>, Bhuvaneshwaran V<sup>2</sup>

1. Senior consultant.  
Department of Uvea, Aditya  
Birla Sankara Nethralaya,  
Kolkata, West Bengal, India

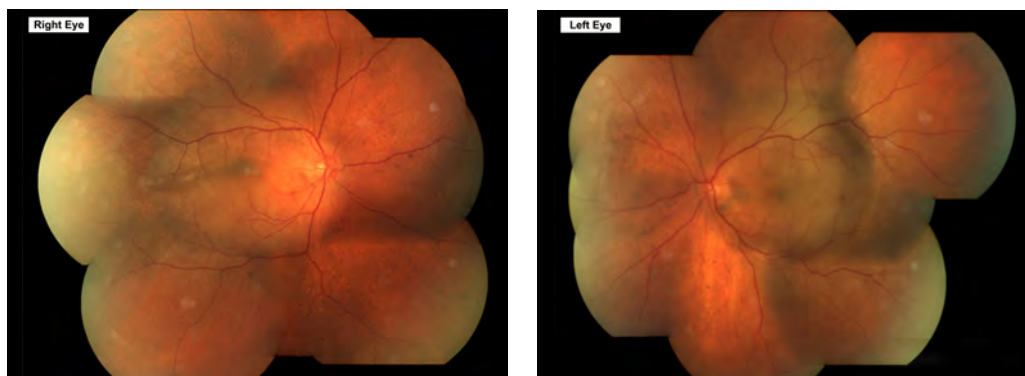2. Fellow, Department of Uvea  
& Medical Retina, Aditya Birla  
Sankara Nethralaya, Kolkata,  
West Bengal, India

Author for Correspondence:

**Amitabh Kumar**

Senior consultant, Department  
of Uvea, Aditya Birla Sankara  
Nethralaya, Kolkata, West  
Bengal, India

drahk@snmail.org



**Fundus photographs showing chronic recurrent VKH**

Vogt-Koyanagi-Harada (VKH) disease is a bilateral granulomatous panuveitis with or without extraocular manifestations. The disease appears to affect women more frequently than men, but no specific gender predilection has been established. Although the actual pathogenesis is unknown, theories revolve around the possibility of a T-cell mediated autoimmune reaction against one or more antigens associated with melanocytes, melanin, S-100 protein, tyrosinase or tyrosinase-related proteins and retinal pigment epithelium (RPE). The primary pathological feature is a diffuse thickening of the uveal tract caused by a non-necrotizing granulomatous inflammation. There is presence of granulomas made of diffuse lymphocytic infiltration with collections of epithelioid cells and multi-nucleated giant cells called the Dalen-Fuchs nodules. The clinical features of VKH disease vary depending on stage of the disease. The four stages of VKH are the prodromal stage, uveitic stage, chronic stage and chronic recurrent stage.

The prodromal symptoms resemble a viral illness like headaches, fever, orbital pain, nausea, dizziness and light sensitivity. The ocular symptoms in the uveitic stage include redness, pain, blurred vision and photophobia. Not infrequently they are misdiagnosed as an acute attack of angle closure glaucoma. The posterior segment findings are vitritis, hyperemia and edema of the optic disk and multiple serous retinal detachments. Chronic stage is characterized by the development of vitiligo, poliosis and depigmentation of the choroid leading to a "sunset-glow fundus." The recurrent stage consists of a panuveitis with acute exacerbations of anterior uveitis. The common complications are cataract, glaucoma and choroidal neovascularization.

The ancillary investigations include Ultrasound B scan, OCT, OCTA, FFA, ICG.

The acute phase is treated with intravenous IV methylprednisolone, oral steroids and immunosuppressive agents like Azathioprine and Mycophenolate mofetil. Recalcitrant cases may require a triple agent immunosuppression with cyclosporine. These patients require a long term treatment and follow up as recurrences are common.

How to cite this article: Kumar A, Bhuvaneshwaran V. Vogt Koyanagi Harada syndrome. Sci J Med & Vis Res Foun 2019; 37 : 29

## Covid19: The Curse and the Cure

Prabrisha Banerjee

---

Orbit Oculoplasty  
Reconstructive and  
Aesthetic Services,  
Aditya Birla Sankara  
Nethralaya, Kolkata, West  
Bengal, India

prabrit.prabrisha@gmail.com

The empty streets of the "Renaissance city"  
Will come back to life once again,  
Lovers' ballad and Beethoven's violin  
Will help to soothe the pain.

The "Charging Bull" will soar high,  
As high as their skyscrapers,  
The Eiffel tower will witness crowds,  
Breaking into song and capers.

The world has a new teacher-  
"Covid19" imparted a vital lesson  
Death does not discriminate,  
It is unbiased to wealth and religion.

The 'white-coats' rose to the occasion  
Saving many, failing a few.  
The 'Nuclear powers' were rendered helpless  
As the demand for ventilators grew.

Animals rejoiced, reclaiming their lands  
People retreated indoors, Mother Nature thrived.  
With her unbound and immense love  
Balance will be restored, humanity will be revived.

## Instructions to the Authors

### Types of Manuscripts

Article Type and Description	Word limit	Maximum references	Maximum Tables and Figures	Types of Study	Abstract
Original articles	2500 (Excluding abstract and references)	30	Maximum 5 including all	<p>Randomized Controlled Trials</p> <p>Prospective Observational / Interventional</p> <p>Retrospective observational / Interventional</p> <p>Descriptive Data</p> <p>Research about diagnostic test / accuracy of tests/modalities</p> <p>Parts – Introduction, Materials &amp; Methods, Results, Discussion, Conclusion &amp; References</p>	Structured abstract (Purpose, Material and Methods, Result and Conclusion) Word limit: 300
Review articles	For Major review- 4000, For Mini review - 3500	No limit for major review 50 for mini review	Maximum 5 figures and 5 tables	<p>Parts –Introduction: Include the statement for your literature search Rest of the portion can be written in different sub headings as per authors' preference</p>	Unstructured abstract Word limit: 300
Case Report / Case Series	1500 (Excluding abstract and references)	12	Maximum 3 including all Authors are suggested to make collages of their images	<p>Case Report – reporting a single case which should be a unique or a rare entity. It should be well documented.</p> <p>Case Series – A minimum of 3 to a maximum of 5 cases on the same entity</p> <p>Parts -Introduction, Case Report, Discussion, Conclusion&amp; References</p>	Unstructured abstract Word limit: 200

Ophthalmic Images	350	Not required	One image with maximum 4 composite pictures	Unique entities or good quality images of routine clinical entities. The images should be self-explanatory	Not required
Nutshell	1500	Not required	Maximum 3 including tables and flowcharts	Invited guest column. Overview of management of a particular ophthalmic ailment. Flowcharts and algorithm format are preferred.	Not required
Letter to the Editor	1000	5	One image with maximum 2 composite pictures	Any opinion regarding previously published articles in the journal and description of a novel technique or a case which raises awareness in the ophthalmological society	Not required
Miscellaneous	700	Optional	Maximum 1 including all	Includes short communication, perspectives, crosswords, poetries or other miscellaneous interesting articles with ophthalmology as the central idea	Not required

**Ethics**

Do not reveal patient’s identity and record number in the manuscript or in the illustrative documents. Do not duplicate other research papers or textual materials. Images reproduced from books, chapters, internet or other articles will require a permission form from the publishers or the owner.

**References**

References should be numbered on the order of their citation in the text. Put the citation in numerical form as superscript after the punctuations. Refer to Vancouver style of quoting the references.

For example:

*Koka K, Alam MS, Subramanian N, Subramanian K, Biswas J, Mukherjee B. Clinical spectrum and management outcomes of Langerhans cell histiocytosis of the orbit. Indian J Ophthalmol 2020;68:1604-8*

For more than six authors, list the first six followed by et al.

For books

Author(s) of the chapter. Title of the chapter. In: Name of the chief editor, editor. Name of the book, edition no. City of publication: Name of the Publisher;Year:page no.

**Tables**

Do not embed the tables in the manuscript. Submit the tables separately as word files.

The tables should be called in the text wherever they are relevant.

The legends for the tables should be mentioned in the header.

The expanded form of the abbreviations should be mentioned in the footnote.

Do not duplicate tables from other text materials.

## **Figures & Illustrations**

All the figures should be in JPEG or TIFF format.

The pictures should be of high resolution (300 dpi).

Maximum of 6 composite pictures are allowed per figure. The pictures should be labelled as “a”, “b” and so on in Ariel font, (black or white text color whichever would serve as a contrast).

All the figures should be numbered and called out consecutively according to the order in which they appear in the manuscript .

Do not embed the figures in the manuscript file or do not send it as a word document. Submit all images separately in the JPEG or TIFF format.

The legends should describe the image briefly (50 words) and should be included in the manuscript file after the references.

## **Presentation Format**

Text font: Times New Roman / Arial

Font size: 12

Double spacing

Headings in title case (not ALL CAPS)

Write the expanded form of each abbreviation at its first use in the title, abstract and text separately, with the abbreviation appearing in the brackets.

Numerals from 1 to 10 spelt out and numerals at the beginning of the sentence should be written in word form and not figure.

## **Submission of Manuscripts**

All manuscripts should be submitted online through mail at email id: drmsa@snmail.org. The submitted manuscripts not adhering to the instructions would be returned to the authors for technical correction.

The manuscript should be submitted in the following parts.

1. Cover Letter
2. Title Page (MS Word file) – The type of the article  
The Title of the article  
Name, designation, and email id of all the authors  
Corresponding author name, his/her designation, and email id  
Total word count (Separately for the abstract and manuscript)
3. Article File (Manuscript and abstract) \
4. Tables (MS Word file)
5. Images – to be submitted as JPEG or TIFF files only.