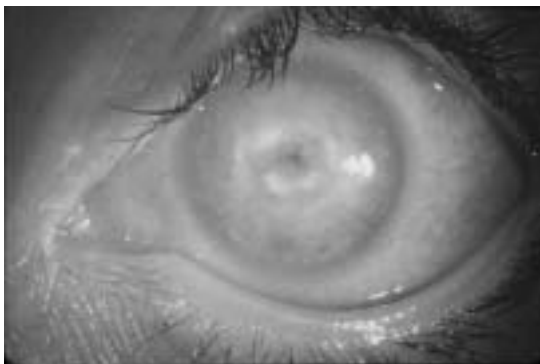


Patient Information

Corneal Ulcer



A defect in the surface of the cornea with a creamy white spot associated with redness. It may be caused by infection or trauma. The infecting organisms can be anything; fungus, bacteria or virus.



Sankara Nethralaya

(A unit of Medical Research Foundation)

18, College Road, Chennai - 600 006. INDIA

Tel. No. : (+91 44) 2827 1616, 2827 1035 Fax : (044) 2825 4180

Email : appointment@sankaranethralaya.org

Web : <http://www.sankaranethralaya.org>

What are the causes of corneal ulcer?

Corneal ulcers are most commonly caused by an infection with bacteria, viruses, fungi. Other causes are abrasions or foreign bodies, inadequate eyelid closure, severe dry eyes, severe allergic eye disease, contact lens wearers and various other inflammatory disorders.

What happens to the Ulcer?

Only a small scar is formed if the ulcer is treated at the early stage. If treatment is delayed, the ulcer leaves a dense scar, which leads to poor visual prognosis.

Treatment :

Treatment of corneal ulcers and infections depends upon the cause, and should be treated as soon as possible to prevent further injury to the cornea. Broad antibiotic coverage is started and then more specific antibiotic, antiviral, or antifungal eye drops are prescribed (as soon as the type of ulcer has been identified). The patient should be checked for his blood glucose level or history of diabetes. Severe ulcers may need to be treated with corneal transplantation.

Corneal Transplant :

If the cornea becomes cloudy, the only way to restore sight is to replace it with a healthy donor cornea through eye donation. Corneal transplantation (keratoplasty) is the most successful of all tissue transplants with an overall success rate greater than 90%. The success rate mostly depends on the cause of the corneal opacity.

Visual Prognosis

Visual Prognosis depends on the site, size of corneal ulcer, time of starting treatment and the complications encountered. All corneal ulcers heal with a scar. If it is in the center of visual axis, refraction of light is affected. If the ulcer is small and situated in the periphery of cornea, it will carry a good prognosis.

Avoid injury to the eyes Wear protective glasses when working in Quarry, Lathe & welding workshops. Upon injury, Consult an eye doctor immediately. Never use home remedies/native medicines in your injured eye. Never use left over medicines for any eye injury. Never use steroids for eye injury.